

Robotic atrial septal defect closure with valved pericardial patch in a pulmonary hypertensive patient

Murat Kadan¹, Gökhan Erol¹, Emre Kubat¹, Mehmet Emin İnce², Tuna Demirkıran¹, Cengiz Bolcal¹

¹Department of Cardiovascular Surgery, Health Sciences University, Gülhane Training and Research Hospital, Ankara, Türkiye

²Department of Anesthesiology and Reanimation, Health Sciences University Gülhane Faculty of Medicine, Ankara, Türkiye

Received: March 02, 2022 Accepted: May 08, 2022 Published online: October 14, 2022

ABSTRACT

Atrial septal defect (ASD) is the most common congenital anomaly in adults after bicuspid aortic valve. Atrial septal defect closure should be carefully considered in the setting of elevated pulmonary artery systolic pressure. Patients with borderline pulmonary vascular resistance may be candidates for closure with careful hemodynamic evaluation, even after pulmonary hypertension therapy. Herein, we present the surgical closure of the ASD with a valved pericardial patch after medical therapy for pulmonary hypertension via the da Vinci robotic system in a 30-year-old female patient.

Keywords: Pulmonary hypertension, robotic atrial septal defect surgery, valved pericardial patch.

Atrial septal defect (ASD) is the most common congenital anomaly in adults after bicuspid aortic valve.^[1] Although it may be asymptomatic until adulthood, potential complications of an undetected ASD include arrhythmias, paradoxical embolizations, right ventricular failure, and pulmonary hypertension, which is associated with high morbidity and mortality rates.^[1,2]

Pulmonary arterial hypertension (PAH) may develop approximately in 3 to 10% of patients with congenital heart disease, known as pulmonary hypertension-congenital heart disease (PH-CHD).^[1] The decision to close an ASD in the presence of elevated pulmonary artery systolic pressures is difficult. In such patients, a cardiac team experienced in congenital heart anomalies must decide the ASD closing surgery. Atrial septal defect closure is contraindicated in patients with Eisenmenger physiology and in patients with pulmonary vascular resistance (PVR) ≥ 5 WU, while it is controversial in patients in the range of 4-5 WU.^[1] In these patient groups, ASD may be crucial for decreasing right ventricle overload by allowing right-to-left shunt as a valve, particularly in pulmonary hypertensive attacks. Therefore, in patients with high pulmonary arterial pressure (PAP), the closing of ASD should be carefully considered after an individualized assessment of patients about potential benefits and risks. A valved pericardial patch could

be a good choice in such patients who are not suitable for interventional techniques with fenestrated ASD closure devices.^[1,2]

In this case report, we present robot-assisted ASD closure with a valved pericardial patch, which allows only a right-to-left shunt, in a patient who had PAH.

CASE REPORT

A 30-year-old female patient with no other known disease was admitted to the cardiology department with reduced functional capacity without any other symptoms. Chest X-ray revealed right atrial enlargement while electrocardiogram demonstrated rightward axis deviation. Transthoracic echocardiography revealed right ventricular dilation, a large ASD, elevated systolic pulmonary artery pressure (85 mmHg), and moderate tricuspid valve insufficiency. Right heart catheterization (RHC) showed an elevated PAP and PVR of 71/31 mmHg

Corresponding author: Murat Kadan, MD, SBÜ Gülhane Eğitim ve Araştırma Hastanesi, Kalp ve Damar Cerrahisi Kliniği, 06010 Keçiören, Ankara, Türkiye.
Tel: +90 506 - 544 85 41 e-mail: muratkadan@yahoo.com

Citation:

Kadan M, Erol G, Kubat E, İnce ME, Demirkıran T, Bolcal C. Robotic atrial septal defect closure with valved pericardial patch in a pulmonary hypertensive patient. Cardiovasc Surg Int 2022;9(3):185-188.

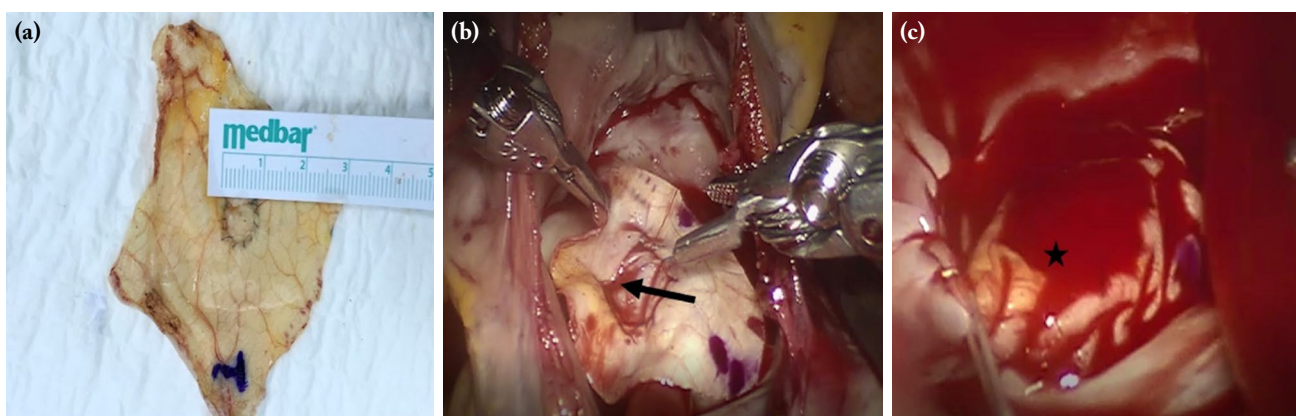


Figure 1. The view of the valved pericardial patch (a) A 1 cm second pericardial patch was sewn onto the hole of the main pericardial patch. (b) The pericardial patch was sutured onto the atrial septal defect. The black arrow shows the direction of the tunnel passing through the inferior vena cava to the superior vena cava. (c) Final version of the valved pericardial patch. Black star indicates the tunnel and the location of the valve).

(mean pressure: 48 mmHg) and 4.74 WU, respectively. The fraction of pulmonary perfusion (Q_p)/fraction of systemic perfusion (Q_s) ratio was 2. Other likely causes of pulmonary hypertension were excluded. We decided to reevaluate ASD surgery after pulmonary hypertension-specific therapy. Macitentan was started 10 mg once daily. Right heart catheterization revealed a slight improvement in PAP (60/33 mmHg [mean pressure: 43 mmHg]) and PVR (3.65 WU) at the three-month follow-up. The Q_p/Q_s ratio was also elevated to 2.85. Although improvements in catheterization parameters, pulmonary hypertension was ongoing. We decided to close the ASD with a valved pericardial patch, which allows only a right-to-left shunt in case of high pressure in the right atrium due to ongoing PAH. Standard surgical procedure was performed via da Vinci robotic system as we detailed in our previous reports.^[2,3] The pericardial patch was excised and treated with glutaraldehyde as usual. Different from standardized ASD surgery, a 1 cm oval defect was created in the middle of the patch. Then, it was repaired with another small pericardial patch with a running polypropylene suture except for one side of the intended defect, which will create a tunnel (as foramen ovale in neonatal life) to allow a right-to-left shunt in case of elevated PAP (Figure 1a). Afterward, the patch was sutured onto the atrial septal defect. At this time, it is important that the small patch stays on the left atrial surface, allowing a right-to-left atrial shunt when it is necessary. Furthermore, a tunnel passing through the inferior vena cava to the

superior vena cava was created (Figure 1b). After the de-airing protocol, the operation was terminated with standardized techniques. Figure 1c demonstrates the final version of the patch. Total cross-clamp time and total perfusion time were 63 and 128 min, respectively. The patient was discharged on the fifth postoperative day without any complications. Macitentan treatment was planned for six months, and a control right heart catheterization was also planned for the six-month follow-up.

DISCUSSION

Atrial septal defect can remain undiagnosed until adulthood. In most asymptomatic patients, symptoms occur after the fourth decade, including reduced functional capacity, exertional shortness of breath, palpitations, and less frequently right heart failure. If pulmonary hypertension has not developed, surgical repair has low mortality and good long-term outcome. However, if pulmonary hypertension has developed, these patients must be carefully evaluated. Atrial septal defect closure is contraindicated in patients with Eisenmenger physiology, a $PVR \geq 5$ WU (despite targeted PAH treatment), or desaturation on exercise.^[4] Nonetheless, there is a gray zone where it is still controversial to close ASD, particularly in patients whose PVR is in the range of 4-5 WU.

According to the European Society of Cardiology guidelines for the management of adult congenital heart disease, patients who have ASD with a significant

shunt (signs of right ventricular volume overload), PVR <5 WU, and $Q_p/Q_s >1.5$ should undergo ASD closure regardless of symptoms.^[5] If PVR is ≥ 5 WU, fenestrated ASD closure may be considered when PVR falls below 5 WU after targeted PAH treatment and a significant shunt is present ($Q_p/Q_s >1.5$). The guidelines also conclude that a decision regarding lesion correction should be based upon individual patient evaluation at a tertiary center with expertise in PH-CHD.^[5] In our case, although the first measured PVR was 4.74, we assessed that it would be risky to completely close the ASD in this patient after hemodynamic evaluation.

There are three commonly used classes of medications that have shown efficacy in PAH treatment: phosphodiesterase-5 inhibitors, prostanoids, and endothelin receptor antagonists. These medications have different pathway targets, mechanisms of action, indications, delivery routes, and side-effect profiles.^[6] In our patient, we chose macitentan (as an endothelin receptor antagonist) for this purpose.

Percutaneous fenestrated ASD closure is undoubtedly an alternative in these patients. However, if it is not feasible to implant the device secondary to a lack of rims (even if it is complete or fenestrated), a surgical valved pericardial patch could be a good choice.

There are some papers about unidirectional valved patch closure of septal defects with good results.^[7,8] With this option, most of the patients who had high surgical risk secondary to complete closure of the ASD could be operated. Rosic et al.^[7] reported their surgical technique with a Dacron patch, which was similar to our technique. It is well-known that autologous pericardium has a stronger ability to resist calcification without any foreign or synthetic material. In our center, we primarily choose autologous pericardium whenever possible, and in this case, we used an autologous pericardium patch instead of a bovine or Dacron patch.

There are several options available to patients for ASD surgery. Percutaneous interventions are less invasive; however, in patients with an insufficient rim of defect, these techniques cannot be used. Shunt recurrency, infections, and occluder dislodgment are other complications of percutaneous techniques.^[9] Therefore, surgeons should continue to prefer safe

and feasible surgical procedures while utilizing less invasive, less traumatic, and most cosmetically appealing techniques. In our center, we do most of the ASD closure surgery with the da Vinci robotic system or minimally invasive techniques. Merits of robotic surgery are mainly less pain, complication, and trauma as in all minimally invasive techniques, with surgeon-friendly instruments' improved mobility and visualization capability.^[9,10] In this regard, robot-assisted valved pericardial ASD closure can be preferred as a cosmetically compelling and effective method for patients with borderline PAH after good hemodynamic evaluation and appropriate medical therapy in a tertiary center.

In conclusion, robot-assisted ASD closure with a valved pericardial patch is an effective and feasible method in pulmonary hypertensive patients after a good hemodynamic evaluation and patient management.

Patient Consent for Publication: A written informed consent was obtained from the patient.

Data Sharing Statement: The data that support the findings of this study are available from the corresponding author upon reasonable request.

Author Contributions: Acquisition, analysis, and interpretation of data. Drafting and revising the manuscript: M.K.; Acquisition, analysis, and interpretation of data. Drafting and revising the manuscript: G.E.; Drafting and revising the manuscript: E.K.; Acquisition of the data. Drafting and revising the manuscript: M.E.İ.; Acquisition, analysis, and interpretation of the data. Drafting and revising the manuscript: T.D.; Acquisition of the data: C.B.

Conflict of Interest: The authors declared no conflicts of interest with respect to the authorship and/or publication of this article.

Funding: The authors received no financial support for the research and/or authorship of this article.

REFERENCES

1. van Riel AC, Schuurin MJ, van Hessen ID, Zwinderman AH, Cozijnsen L, Reichert CL, et al. Contemporary prevalence of pulmonary arterial hypertension in adult congenital heart disease following the updated clinical classification. *Int J Cardiol* 2014;174:299-305.
2. Demirkilic U, Kadan M, Doganci S, Bolcal C, Yildirim V, Alhan C. Unrecognized indication for robot-assisted cardiac surgery: Patients with acute psychotic disorders. *Minim Invasive Ther Allied Technol* 2016;25:117-9.
3. Kadan M, Kubat E, Erol G, Karabacak K, Akyol FB, Yildirim V, et al. Early- and mid-term results of cryoablation of atrial

- fibrillation concomitant with robotic mitral valve surgery. *Anatol J Cardiol* 2021;25:266-72.
4. Galiè N, Humbert M, Vachiery JL, Gibbs S, Lang I, Torbicki A, et al. 2015 ESC/ERS Guidelines for the diagnosis and treatment of pulmonary hypertension: The Joint Task Force for the Diagnosis and Treatment of Pulmonary Hypertension of the European Society of Cardiology (ESC) and the European Respiratory Society (ERS): Endorsed by: Association for European Paediatric and Congenital Cardiology (AEPC), International Society for Heart and Lung Transplantation (ISHLT). *Eur Respir J* 2015;46:903-75.
 5. Baumgartner H, De Backer J. The ESC clinical practice guidelines for the management of adult congenital heart disease 2020. *Eur Heart J* 2020;41:4153-4.
 6. Doganci S, Yildirim V, Yesildal F, Erol G, Kadan M, Ozkan G, et al. Comparison of angiogenic and proliferative effects of three commonly used agents for pulmonary artery hypertension (sildenafil, iloprost, bosentan): Is angiogenesis always beneficial? *Eur Rev Med Pharmacol Sci* 2015;19:1900-6.
 7. Rosic M, Susak S, Redzek A, Velicki L. Closure of an atrial septal defect with a one-way flap patch in a patient with severe pulmonary hypertension. *Interact Cardiovasc Thorac Surg* 2016;22:856-8.
 8. Ugurlucan M, Arslan AH, Yildiz Y, Cicek S. eComment. An oval-shaped unidirectional check-valved patch for treating ventricular septal defects. *Interact Cardiovasc Thorac Surg* 2012;14:702.
 9. Senay S, Gullu AU, Kocyigit M, Degirmencioglu A, Karabulut H, Alhan C. Robotic atrial septal defect closure. *Multimed Man Cardiothorac Surg* 2014;2014:mmu014.
 10. Sicim H, Kadan M, Erol G, Yildirim V, Bolcal C, Demirkilic U. Comparison of postoperative outcomes between robotic mitral valve replacement and conventional mitral valve replacement. *J Card Surg* 2021;36:1411-8.