

Penetrating cardiac trauma mimicking congenital sinus Valsalva aneurysm rupture: A case report

Ahmet Barış Durukan¹, Ahmet Ünlü¹, Ali Cevat Tanalp²

¹Department of Cardiovascular Surgery, Medical Park Uşak Hospital, Uşak, Turkey

²Department of Cardiology, Medical Park Uşak Hospital, Uşak, Turkey

Received: February 08, 2018 **Accepted:** September 03, 2018 **Published online:** April 24, 2019

ABSTRACT

Penetrating cardiac injuries are rare, but often fatal. They may present with different manifestations. A 30-year-old male patient was admitted with self-inflicted left parasternal stab wound in the second intercostal space. Computed tomography revealed pericardial and pleural effusion. Echocardiography and aortography showed severe aortic regurgitation and aorto-right ventricular communication mimicking a congenital sinus Valsalva aneurysm rupture. The patient was operated and aortic leaflet repair with a pericardial patch and closure of the communication on both aortic and right ventricular sides were performed. In conclusion, although such traumatic injuries are rare, they may be life-threatening and, therefore, requires prompt treatment.

Keywords: Congenital sinus; heart injuries; penetrating injuries; Valsalva aneurysm rupture.

Penetrating cardiac injuries are rare, but represent a high mortality in most cases. The injury is usually non-accidental, predominantly sustained by males, and the mortality rate is about 60%, which further increases where pericardial tamponade is absent.^[1,2] In a recent large series, 86% of injuries constituted single chamber injury, predominantly right ventricle (46%) and left ventricle (24%), whereas multi-chamber injuries were seen in 18% of cases. Patients typically manifest with signs of cardiac tamponade, cardiac arrest, or signs of extremis from exsanguination.^[2]

Congenital sinus Valsalva aneurysms are rare abnormalities often presenting with rupture. In more than 80% of cases, the rupture originates from the right coronary sinus (RCS). Aorto-right ventricular connection is observed in 65% of cases.^[3,4]

Herein, we report a case of aorto-right ventricular communication concomitant with aortic regurgitation due to self-inflicted stab wound injury.

He was examined in a rural medical center and the skin wound was sutured. The patient reported no complaint subsequently. Echocardiography and aortography revealed aortic valve regurgitation due to a defect in the right coronary cusp (RCC) and aorto-right ventricular communication (Video 1). Pericardial and bilateral pleural effusion was noted on echocardiography and computed tomography (CT) scan (Figure 1a). He had no signs of tamponade or pathological findings, except for the sutured wound (Figure 1b).

He was scheduled for an urgent operation and a written informed consent was obtained. A median sternotomy was performed. Due to the possibility of aortic injury, right femoral artery was cannulated to initiate cardiopulmonary bypass (CPB) immediately following pericardiotomy. Hematoma and defibrinated blood were present in the pericardial space. A very little adventitial hematoma was located in the left lateral side of the aorta above the sinotubular

CASE REPORT

A 30-year-old male patient was admitted to the cardiology department with chest pain. He had a self-inflicted left parasternal stab wound in the second intercostal space two days ago after heavy alcohol intake. He did not remember the type of knife used.

Corresponding author: Ahmet Barış Durukan, MD. Medical Park Uşak Hastanesi Kalp ve Damar Cerrahisi Bölümü, 64200 Uşak, Turkey.
Tel: +90 276 - 227 22 33 e-mail: barisdurukan@yahoo.com

Citation:

Durukan AB, Ünlü A, Tanalp AC. Penetrating cardiac trauma mimicking congenital sinus Valsalva aneurysm rupture: A case report. *Cardiovasc Surg Int* 2018;5(3):40-42.

junction. The right atrium was cannulated and CPB was initiated. Transverse aortotomy was performed. There was a slit-like linear opening on RCS connected with right ventricular cavity (Figure 1c). There was also a 2×1 cm defect in the RCC. Transverse right ventriculotomy was performed to visualize the opening of the defect and a slit-like linear opening was noted (Figure 1d).

The aortic side of the opening was sutured with two Teflon pledgeted sutures (Figure 1e) and the right ventricular side with the Teflon felt on both sides (Figure 1f). The defect in the RCC was repaired with a fresh pericardial patch. Aortotomy was closed and the patient was weaned

from CPB. The postoperative course was uneventful and postoperative echocardiography revealed no aortic regurgitation or aorto-right ventricular communication. In the first year of follow-up, the patient is still stable with normal echocardiographic findings.

DISCUSSION

Penetrating cardiac injury is often fatal with a mortality rate over 60%. Multi-chamber injuries constitute a lower percentage of cases with a predominant single right ventricle injury.^[1,2] The present case is unique, as it is a late admission and had no signs of hemodynamic compromise,

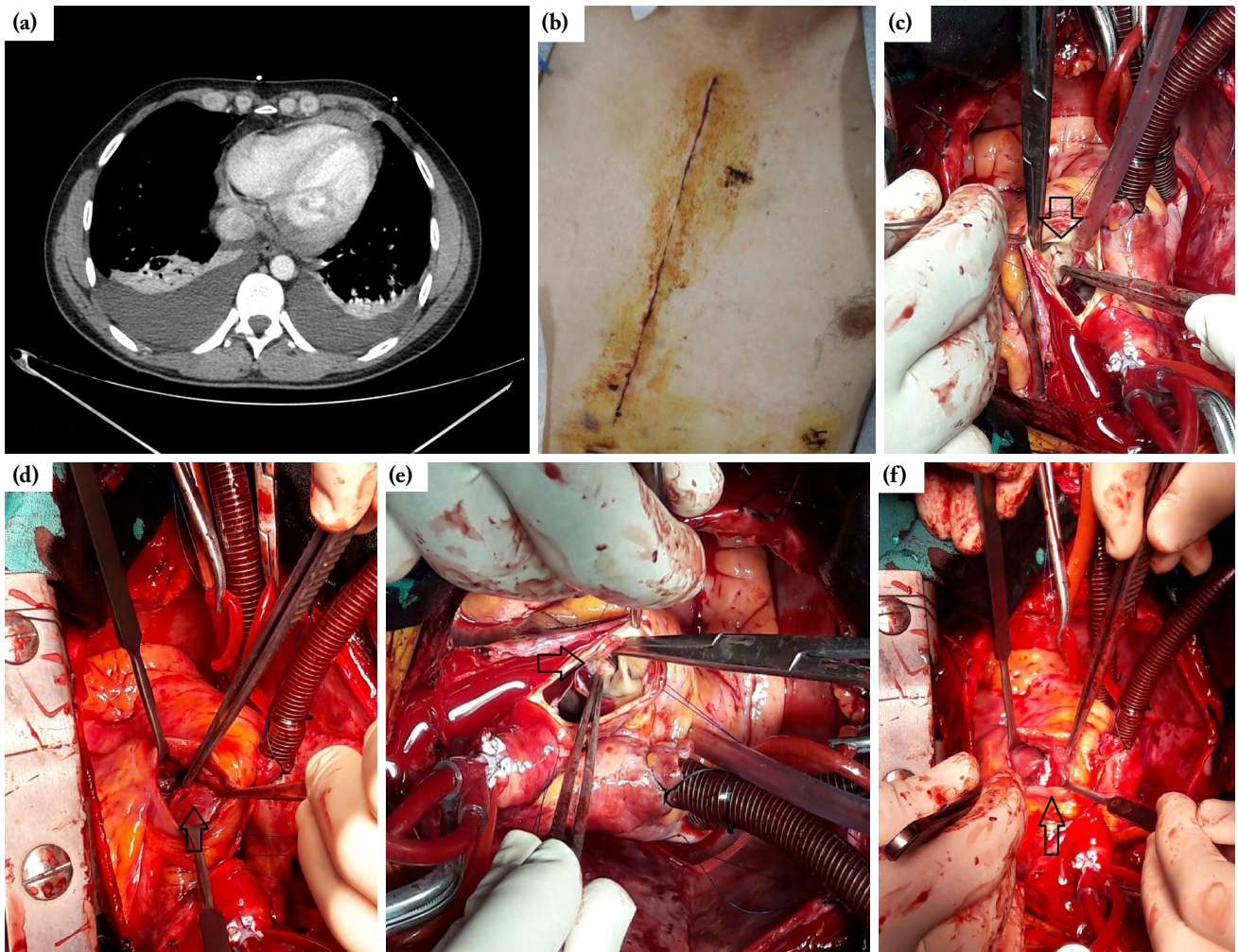


Figure 1. (a) Computed tomography scan showing pericardial and bilateral pleural effusion. (b) The stab wound injury in the second left parasternal intercostal space. (c) Aortic slit-like linear injury (arrow). (d) Right ventricular slit-like linear injury (arrow). (e) Aortic side of repair with two Teflon pledgeted sutures (arrow). (f) Right ventricular side of repair with over and over suture supported with Teflon felts on both sides (arrow).

despite a great injury with an aorto-right ventricular communication.

Such an injury might have caused a great hemodynamic compromise due to signs of exsanguination or cardiac tamponade. However, our case had no complaints at the time of injury and was admitted two days later due to chest pain. Surprisingly, pericardial effusion was not much and did not cause tamponade within two days. There was a small adventitial hematoma in the left lateral side of the aorta, however, there was neither hemorrhage from the aorta nor a visible aortic injury site. In this case, the injury mimicked a ruptured congenital sinus Valsalva aneurysm, although it was truly a multi-chamber injury involving the ascending aorta. The RCC was also injured and repaired with a pericardial patch.

There is a limited number of reports in the literature showing similar pathologies.^[5,6] Such an injury may be fatal at the time of injury, and it is quite surprising that our patient survived. In addition, he did not remember the type of knife used, although we suspected a skewer-like thin and long tool.

In conclusion, penetrating cardiac injuries may represent as unique pathologies and require major interventions. If possible, repair should be preferred, if valvular pathologies exist.

Declaration of conflicting interests

The authors declared no conflicts of interest with respect to the authorship and/or publication of this article.

Funding

The authors received no financial support for the research and/or authorship of this article.

REFERENCES

1. Connelly TM, Kolcow W, Veerasingam D, DaCosta M. A severe penetrating cardiac injury in the absence of cardiac tamponade. *Interact Cardiovasc Thorac Surg* 2017;24:286-87.
2. Morse BC, Mina MJ, Carr JS, Jhunjhunwala R, Dente CJ, Zink JU, et al. Penetrating cardiac injuries: A 36-year perspective at an urban, Level I trauma center. *J Trauma Acute Care Surg* 2016;81:623-31.
3. Abralov K, Alimov A. Short-term results of sinus of valsalva aneurysm repair. *World J Pediatr Congenit Heart Surg* 2017;8:13-7.
4. Yadav A, Mathur R, Devgarha S, Abraham V, Sisoida A. Surgery for ruptured sinus of Valsalva aneurysm: Five-year experience with 19 patients. *Turk Gogus Kalp Dama* 2014;22:729-33.
5. Esfahanizadeh J, Abbasi Tashnizi M, Moeinipour AA, Sepehri Shamloo A. undetected aorto-rv fistula with aortic valve injury and delayed cardiac tamponade following a chest stab wound: a case report. *Trauma Mon* 2013;18:95-7.
6. Kaya A, Dekkers P, Loforte A, Jaarsma W, Morshuis WJ. Traumatic aorto-right ventricular fistula with aortic insufficiency. *Ann Thorac Surg* 2005;80:2362-4.