

## Intraplaque hemorrhage causing recurrent stroke treated by carotid endarterectomy

Serkan Ertugay<sup>1</sup>, Cenk Eraslan<sup>2</sup>, Hakan Posacıoğlu<sup>1</sup>

<sup>1</sup>Department of Cardiovascular Surgery, Ege University Faculty of Medicine, Izmir, Turkey

<sup>2</sup>Department of Radiology, Ege University Faculty of Medicine, Izmir, Turkey

Received: March 06, 2019 Accepted: May 17, 2019 Published online: March 16, 2020

### ABSTRACT

Atherosclerotic plaque characteristics such as intraplaque hemorrhage, thickness of fibrous cap and large lipid-rich necrotic core are the predictors of future cerebrovascular events. Those features are examined by vessel wall magnetic resonance imaging. In this article, we present a 60-year-old male patient who underwent carotid endarterectomy because of intraplaque hemorrhage causing recurrent transient ischemic attacks. Because of the recurrent ischemic attacks, carotid endarterectomy was performed emergently. Patient was discharged after uneventful postoperative course. Vessel wall magnetic resonance imaging is the advanced evaluation of carotid artery disease which determines high-risk plaque according to intraplaque hemorrhage and thin fibrous cap. In case of recurrent symptoms and presence of high-risk plaque, carotid intervention should be considered regardless of the degree of stenosis.

**Keywords:** Atherosclerosis, carotid artery disease, intraplaque hemorrhage, magnetic resonance imaging.

According to guidelines, the recommendation of carotid endarterectomy (CEA) or carotid artery stenting for carotid artery disease (CAD) is based on the degree of stenosis, presence of symptoms and the risk of CEA.<sup>[1]</sup> However, plaque characteristics of vulnerability may also predict future cerebrovascular events.<sup>[2,3]</sup> Doppler ultrasonography (US) and computed tomography (CT) are used commonly at first step for the diagnosis of CAD. Besides, vessel wall magnetic resonance imaging (MRI) has the advantages to demonstrate high-risk carotid plaque characteristics. In this article, we present a patient who underwent CEA because of intraplaque hemorrhage (IPH) causing recurrent transient ischemic attacks.

### CASE REPORT

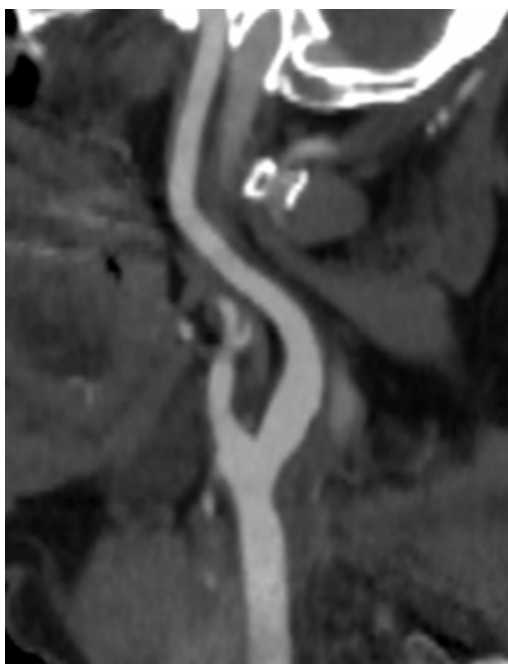
A 60-year-old male patient, without history of risk factor for atherosclerosis, presented with transient ischemic attack causing dysarthria and weakness on right side of the body. After the onset of the symptoms, diffusion weighted MRI study (Siemens Verio 3 Tesla System, Erlangen, Germany, Diffusion B1000 images/apparent diffusion coefficient maps) showed multiple acute infarct areas on right cerebral hemisphere. The infarct areas were located within bilateral centrum semiovale. With the intent of etiologic evaluation, carotid Doppler US revealed atherosclerotic carotid

plaque with non-significant stenosis on the left side. Computed tomography angiography showed atherosclerotic plaque without significant narrowing in the left carotid artery (Figure 1). Transesophageal echocardiography showed small plaque on arcus aorta which was not ulcerated. Patient was treated with acetylsalicylic acid and unfractionated heparin. He was discharged with optimal medical treatment including dual antiplatelet therapy, lipid lowering and antihypertensive drug. Two days later, patient was readmitted with recurrent ischemic attack. Vessel wall imaging (T2 axial fat saturated turbo spin-echo, T1 pre-contrast fat saturated axial, T1 post-contrast fat saturated images; diffusion B200, B400 images) was performed. Intraplaque hemorrhage was detected into the atherosclerotic plaque located in the left carotid bifurcation (Figure 2). Because of recurrent attacks, CEA was performed urgently. As surgical approach, endarterectomy was performed by conventional technique without using patch or shunt. Macroscopic view of the plaque confirmed large area of plaque

**Corresponding author:** Serkan Ertugay, MD. Ege Üniversitesi Tıp Fakültesi Kalp ve Damar Cerrahisi Anabilim Dalı, 35100 Bornova, İzmir, Türkiye.  
Tel: +90 232 - 390 40 49 e-mail: serkanertugay80@gmail.com

### Citation:

Ertugay S, Eraslan C, Posacıoğlu H. Intraplaque hemorrhage causing recurrent stroke treated by carotid endarterectomy. *Cardiovasc Surg Int* 2019;6(3):38-40.

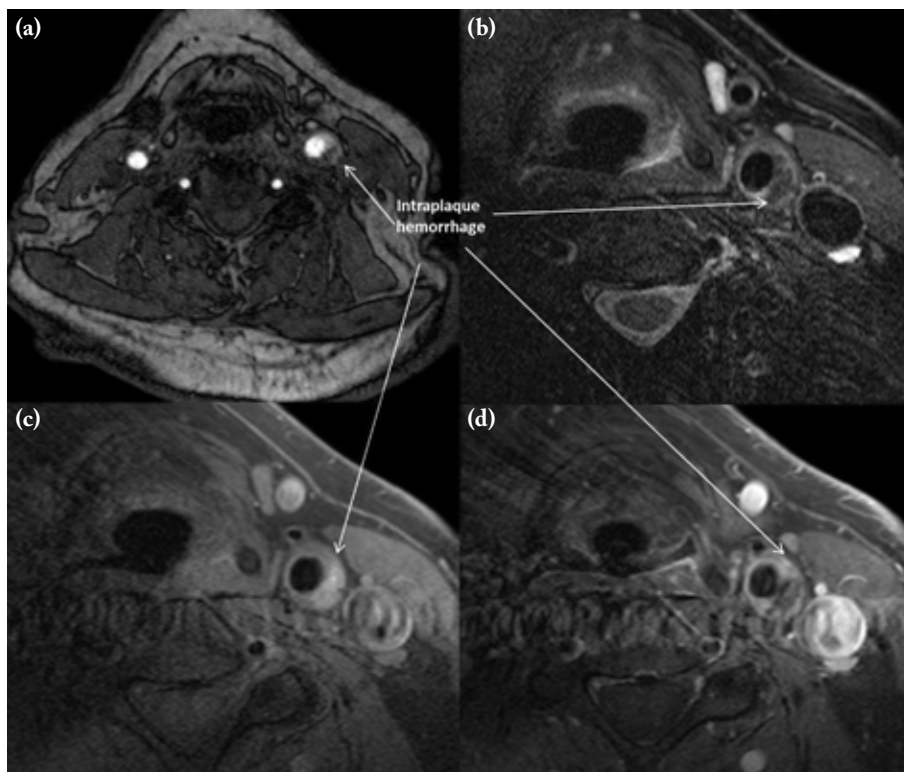


**Figure 1.** Reconstructed minimum intensity projection computed tomography angiography image showing plaque without significant stenosis.

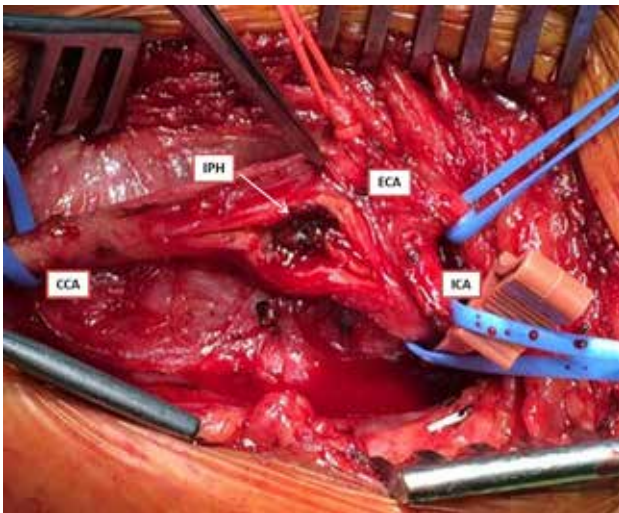
hemorrhage (Figure 3). Time interval between the onset of symptoms and surgery was four days. Patient was discharged with dual antiplatelet, statin and antihypertensive drugs after uneventful postoperative course. During follow-up, he was asymptomatic which confirmed that ischemic attacks were caused by the IPH. A written informed consent was obtained from the patient.

## DISCUSSION

Doppler scanning is usually the first step of the diagnostic algorithm of ischemic stroke. Angiographic (CT or digital subtraction) evaluation of carotid plaque is needed to determine the severity of stenosis and to plan any intervention. However, MRI has the advantages to detect plaque morphology and composition in addition to stenosis. Diffusion weighted MRI is the main imaging modality to diagnose infarct after ischemic stroke. Further evaluation of plaque characteristics by vessel wall MRI such as IPH, lipid-rich necrotic core, and thickness of fibrous cap determines its vulnerability. Zhao et al.<sup>[2]</sup> found



**Figure 2.** (a) Time-of-flight magnetic resonance angiography image. (b) T2 axial fat saturated image. (c) T1 axial fat saturated image. (d) T1 axial post-contrast fat saturated image at level of hemorrhagic plaque.



**Figure 3.** Intraoperative view of intraplaque hemorrhage located in carotid bifurcation.

CCA: Common carotid artery; ECA: External carotid artery; ICA: Internal carotid artery; IPH: Intraplaque hemorrhage.

that presence of those features is commonly related to the degree of stenosis. Furthermore, IPH was not detected in patients with carotid stenosis of less than 30% in this study. Unlikely, in our case, despite non-significant stenosis, IPH was large and the major cause of recurrent stroke attacks.

These features were analyzed to predict future ischemic events in patients with CAD. Virmani et al.<sup>[4]</sup> described that atherosclerotic plaque with thin fibrous cap (<0.2 mm) and distinct lipid-rich necrotic core carries a high risk of rupture in coronary artery disease. In line with this, in their study based on MRI, Gijzen et al.<sup>[5]</sup> have analyzed plaque composition which creates peak cap stress and found a significant association between thin fibrous cap atheroma and high peak stress. Intraplaque hemorrhage is the other common feature of carotid plaque which may cause stroke. Intraplaque hemorrhage is the result of ruptured neovascularization and commonly cause fibrous cap disruption.<sup>[6]</sup> However, to date, there is still no evidence-based recommendation suggesting carotid intervention according to plaque composition in patients with low degree of stenosis. In this case,

recurrent ischemic stroke was the main indication for intervention despite optimal medical therapy. Vessel wall MRI revealed IPH causing recurrent events which required urgent CEA.

In conclusion, features of vulnerable carotid plaque, such as intraplaque hemorrhage and thin fibrous cap, are predictors of future stroke and can be identified by magnetic resonance imaging. In case of recurrent symptoms caused by high-risk plaque despite optimal medical therapy, carotid endarterectomy might be considered regardless of the degree of stenosis.

#### Declaration of conflicting interests

The authors declared no conflicts of interest with respect to the authorship and/or publication of this article.

#### Funding

The authors received no financial support for the research and/or authorship of this article.

## REFERENCES

1. Abbott AL, Paraskevas KI, Kakkos SK, Golledge J, Eckstein HH, Diaz-Sandoval LJ, et al. Systematic Review of Guidelines for the Management of Asymptomatic and Symptomatic Carotid Stenosis. *Stroke* 2015;46:3288-301.
2. Zhao H, Zhao X, Liu X, Cao Y, Hippe DS, Sun J, et al. Association of carotid atherosclerotic plaque features with acute ischemic stroke: a magnetic resonance imaging study. *Eur J Radiol* 2013;82:e465-70.
3. Gupta A, Baradaran H, Schweitzer AD, Kamel H, Pandya A, Delgado D, et al. Carotid plaque MRI and stroke risk: a systematic review and meta-analysis. *Stroke* 2013;44:3071-7.
4. Virmani R, Kolodgie FD, Burke AP, Farb A, Schwartz SM. Lessons from sudden coronary death: a comprehensive morphological classification scheme for atherosclerotic lesions. *Arterioscler Thromb Vasc Biol* 2000;20:1262-75.
5. Gijzen FJ, Nieuwstadt HA, Wentzel JJ, Verhagen HJ, van der Lugt A, van der Steen AF. Carotid plaque morphological classification compared with biomechanical cap stress: Implications for a magnetic resonance imaging-based assessment. *Stroke* 2015;46:2124-8.
6. Kawahara I, Nakamoto M, Hayashi K, Kitagawa N, Tsutsumi K, Nagata I, et al. The detection of carotid plaque rupture caused by intraplaque hemorrhage by serial high-resolution magnetic resonance imaging: a case report. *Surg Neurol* 2008;70:634-9.