

Giant asymptomatic pulmonary herniation following minimally invasive mitral valve replacement

Ahmet Barış Durukan¹, Alper Canbay², Ertan Aydın³

¹Department of Cardiovascular Surgery, Liv Ankara Hospital, Ankara, Türkiye

²Department of Cardiology, Liv Ankara Hospital, Ankara, Türkiye

³Department of Thoracic Surgery, Liv Ankara Hospital, Ankara, Türkiye

Received: December 13, 2022 Accepted: January 29, 2023 Published online: March 27, 2023

ABSTRACT

Minimally invasive valve procedures have become the standard procedure for valvular surgery. Right thoracotomy is the preferred incision for mitral or tricuspid interventions. Complications regarding thoracotomy are almost always either overlooked or ignored. Pulmonary herniation is not that infrequent, but mostly asymptomatic or masked. Pulmonary herniation through thoracotomy incision is the most common presentation and is usually in a limited area. Herein, we present a 62-year-old female patient with giant pulmonary herniation that did not cause any respiratory issues following minimally invasive mitral valve surgery. No treatment was required for pulmonary herniation. She was only given full medical therapy for heart failure.

Keywords: Minimally invasive surgical procedures, pulmonary herniation, thoracotomy.

Minimally invasive cardiac surgery is a frequently preferred option in the last two decades for surgical valvular procedures, predominantly right thoracotomy approach for mitral or tricuspid pathologies.^[1] The implemented advantages over applicability and durability of the procedure include lower pain and discomfort easing earlier return to normal life.^[2] However, reported drawbacks often include recurrent valvular pathologies, and often incision-related complications are either overlooked or ignored and not reported. Pulmonary herniation is an incision-related complication following minimally invasive valvular procedures. Herein, we report a case of giant pulmonary herniation following right thoracotomy approach mitral valve replacement surgery that does not cause any respiratory issues.

CASE REPORT

A 62-year-old hospitalized female patient treated for heart failure was consulted with us for a visible lung herniation during respiration. The patient had a visible in-and-out movement of the respiratory wall due to inflated and deflated pulmonary tissue, and the herniated chest wall only consisted of skin and subcutaneous tissue (Figure 1a and Video 1). A mitral valve replacement surgery with the right

thoracotomy approach was performed seven years ago in a different center. The postoperative course was eventful, with femoral access site nosocomial infection treated with vacuum-assisted therapy. The patient had a minor hernia that did not cause any respiratory symptoms located above the incision, which had gradually increased in size over the years.

Plain chest X-ray revealed complete 12 ribs on the right side (no ribs were excised or removed during surgery), and computed tomography scan documented a great area of herniation of the pulmonary tissue (Figure 1b).

The patient had a pacemaker implanted and advanced heart failure. The patient was left untreated for the hernia since it was asymptomatic, and the medical status of the patient would not allow a chest wall repair surgery under general anesthesia.

Corresponding author: Ahmet Barış Durukan, MD. Liv Ankara Hastanesi Kalp ve Damar Cerrahisi Bölümü, 06680 Çankaya, Ankara, Türkiye.
E-mail: barisdurukan@yahoo.com

Citation:

Durukan AB, Canbay A, Aydın E. Giant asymptomatic pulmonary herniation following minimally invasive mitral valve replacement. *Cardiovasc Surg Int* 2023;10(1):72-74. doi: 10.5606/e-cvsi.2023.1475.

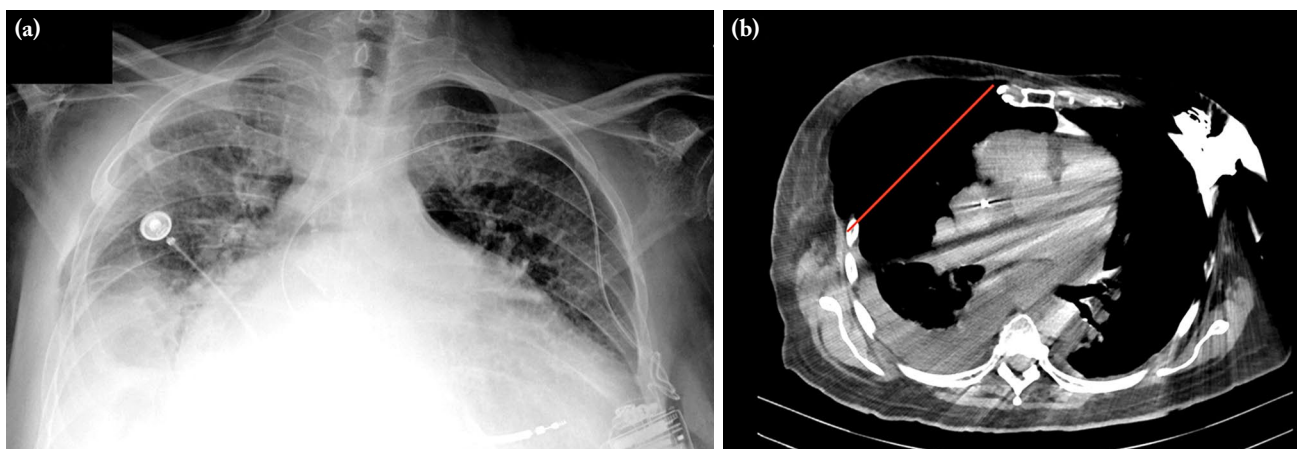
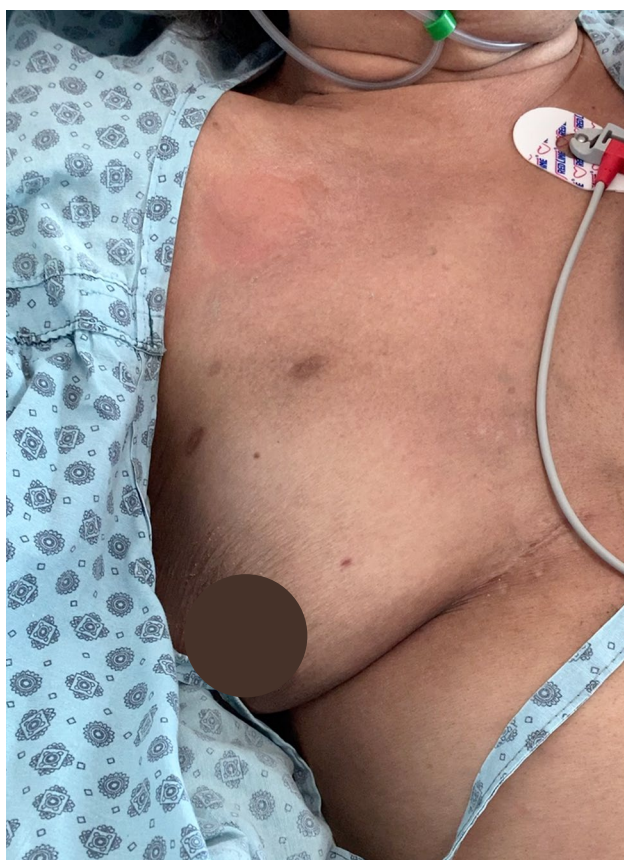

Figure 1. (a) Chest wall with complete 12 ribs on X-ray. (b) Computed tomography scan documenting a great area of herniated pulmonary tissue (red line).



Video 1. Respiratory pattern of the patient.

DISCUSSION

Pulmonary herniation is an infrequent diagnosis, which can be either congenital or acquired; the latter being traumatic, spontaneous, or pathologic. It can

be occasionally encountered following thoracotomy. Herniation is usually visible in males in contrast to females since breast tissue masks the herniated tissue. Patients usually complain of pain during coughing. Unlike the patient presented here, patients may complain of a persistent cough, dyspnea, and haemoptysis.^[3] Treatment is surgical with autologous graft chest wall reconstruction.^[4] The pathology itself is not infrequent following surgical valvular procedures with the right thoracotomy approach but is mostly overlooked or ignored and consequently not reported.

A detailed report of 20 cases stated that pulmonary herniation was an infrequent entity and minor herniations were more common.^[4] The patient we reported has a very large area of pulmonary herniation, but the pathology did not cause any respiratory problem. The chest wall was flail with only skin and subcutaneous tissue covering the lungs. The patient's dyspnea was caused by cardiac failure rather than pulmonary herniation.

In conclusion, it should be kept in mind that pulmonary herniation may occur following minimally invasive mitral valve surgery. Minor herniations are more frequent. The treatment varies depending upon patient's condition.

Patient Consent for Publication: A written informed consent was obtained from patient.

Data Sharing Statement: The data that support the findings of this study are available from the corresponding author upon reasonable request.

Author Contributions: All authors contributed equally to the article.

Conflict of Interest: The authors declared no conflicts of interest with respect to the authorship and/or publication of this article.

Funding: The authors received no financial support for the research and/or authorship of this article.

REFERENCES

1. Kofidis T, Chang G. How to set up a minimally invasive cardiac surgery program? *Turk Gogus Kalp Dama* 2020;28:571-5. doi: 10.5606/tgkdc.dergisi.2020.09356.
2. Nakayama T, Nakamura Y, Yasumoto Y, Yoshiyama D, Kuroda M, Nishijima S, et al. Early and mid-term outcomes of minimally invasive mitral valve repair via right mini-thoracotomy: 5-year experience with 129 consecutive patients. *Gen Thorac Cardiovasc Surg* 2021;69:1174-84. doi: 10.1007/s11748-020-01573-2.
3. Mhamdi S, Aouini I, Daboussi S, Mahfoudhi H, Lassoued MB, Kallel M, et al. Intercostal lung herniation secondary to thoracotomy: A case report. *Pan Afr Med J* 2020;36:39. doi: 10.11604/pamj.2020.36.39.20054.
4. Cetinkaya A, Zeriuoh M, Liakopoulos OJ, Hein S, Siemons T, Bramlage P, et al. Pulmonary herniation after minimally invasive cardiac surgery: Review and implications from a series of 20 cases. *J Surg Case Rep* 2020;2020:rjaa415. doi: 10.1093/jscr/rjaa415.