

## Transthoracic echocardiographic evaluation of cardiac remodeling after thoracic endovascular aortic repair

Sabir Hasanzade<sup>1</sup>, Serkan Mola<sup>2</sup>, Ayla Ece Çelikten<sup>3</sup>, Murat Gevrek<sup>2</sup>, Baran Karadeniz<sup>2</sup>, Görkem Yiğit<sup>3</sup>, Hakkı Zafer İşcan<sup>2</sup>

<sup>1</sup>Department of Cardiovascular Surgery, Memorial Ankara Hospital, Ankara, Türkiye

<sup>2</sup>Department of Cardiovascular Surgery, Ankara Bilkent City Hospital, Ankara, Türkiye

<sup>3</sup>Department of Cardiovascular Surgery, Hitit University Erol Olçok Training and Research Hospital, Çorum, Türkiye

Received: January 14, 2024 Accepted: February 20, 2024 Published online: March 25, 2024

### ABSTRACT

**Objectives:** This study aimed to evaluate post-thoracic endovascular aortic repair (TEVAR) cardiac remodeling with transthoracic echocardiography.

**Patients and methods:** Thirty-two patients (27 males, 5 females; mean age: 61±12.8 years; range, 27 to 85 years) who underwent TEVAR, with an Ishimura zone 3 proximal landing zone, due to thoracic aortic aneurysm were retrospectively evaluated between January 2019 and January 2023. Pre- and postprocedural transthoracic echocardiography data of the patients were compared. Measurements of left ventricular end-diastolic diameter, left ventricular ejection fraction, interventricular septum, and ascending aorta were performed.

**Results:** The mean follow-up period was 23.7±8.4 months. There was a significant increase in interventricular septum measurements (p=0.041). In addition, a significant decrement was observed in the comparison of left ventricular ejection fraction values (p=0.01). There was no difference found at the pre- and post-TEVAR ascending aortic diameters or valvular regurgitation in aortic valves.

**Conclusion:** Despite our evaluation being conducted in a limited patient population, our findings suggest that the stiffening of the aortic structure after TEVAR has a negative impact on cardiac remodeling. Consequently, it is imperative to explore new and more flexible designs for thoracic endograft structures.

**Keywords:** Aorta, endovascular aneurysm repair, left ventricular remodeling, thoracic aortic aneurysm, transthoracic echocardiography.

Thoracic endovascular aortic repair (TEVAR) has become the preferred treatment method for thoracic aortic aneurysms (TAAs) for anatomically suitable patients in recent years due to its lower mortality and morbidity rates in the early- and mid-term compared to open surgical repair.<sup>[1-3]</sup>

However, for long-term follow-up, cardiac mortality is still one of the leading causes of late mortalities, maybe due to associated coronary artery disease or comorbidities. In recent years, another important factor was also argued for late mortalities and cardiovascular complications: aortic stiffness created by TEVAR endografts. Aortic stiffening is known to play a crucial role in the development and progression of cardiovascular diseases.<sup>[4,5]</sup> Moreover, the compliance of the aorta is essential in reducing the workload of the heart. Experimental studies have shown that increased aortic stiffness after TEVAR may result from the complex interaction between the

aorta and the endograft.<sup>[6-8]</sup> The motionless state of the arch and proximal descending aorta in patients who underwent TEVAR may be the reason for aortic stiffness. Therefore, designing more flexible and physiological endografts may lead to better results. Afterload reduction by medical treatment may be another important issue. The aortic arch contributes significantly to arterial compliance; therefore, TEVAR may have a negative impact on compliance, increasing left ventricular afterload and myocardial

**Corresponding author:** Ayla Ece Çelikten, MD. Hitit Üniversitesi Erol Olçok Eğitim ve Araştırma Hastanesi, Kalp ve Damar Cerrahisi Kliniği, 19040 Çorum, Türkiye.

E-mail: aecelikten@gmail.com

### Citation:

Hasanzade S, Mola S, Çelikten AE, Gevrek M, Karadeniz B. Transthoracic echocardiographic evaluation of cardiac remodeling after thoracic endovascular aortic repair. *Cardiovasc Surg Int* 2024;11(1):64-69. doi: 10.5606/e-cvsi.2024.1595.

energy requirements.<sup>[9,10]</sup> This issue needs further investigation with larger series with comparison of different endografts, different landing zones at the descending aorta, and post-TEVAR medications. Therefore, new designs or materials able to minimize their impact on pulse wave profile and aortic wall mechanical properties may be the next step.<sup>[11]</sup>

This study aimed to evaluate the echocardiographic changes after TEVAR in TAAs where the proximal landing zone was Ishimura zone 3.

## PATIENTS AND METHODS

The data of 108 patients who underwent TEVAR due to TAA at the Ankara Bilkent City Hospital between January 2019 and January 2023 were retrospectively evaluated, and 32 eligible patients (27 males, 5 females; mean age: 61±12.8 years; range, 27 to 85 years) were included in the study. Patients with available pre- and post-TEVAR echocardiography and computed tomography angiography were included. All patients had proximal landing zones at Ishimura zone 3. Other proximal landing zones were excluded. Aortic dissections, prior surgical or endovascular aortic repair, and emergent cases in which transthoracic echocardiography could not be performed before the procedure were excluded from the study.

### Procedural details and management strategy

Patients who underwent TEVAR procedures using the technique described in our previous article.<sup>[12]</sup> All procedures were successfully performed without complications. The endografts for all patients were placed with proximal attachment zones in Ishimura zone 3 (Figure 1). Zone 3 was thought to interfere with aortic stiffness the most as it was the starting point of a standard TEVAR procedure at the descending aorta.

In the intensive care unit following TEVAR, either intravenous beta-blockers or calcium channel blockers, administered individually or in combination, were employed as an initial therapy to bring down systolic blood pressure to less than 120 mmHg. Out of the 32 patients, around 24 (75%) individuals had a documented history of hypertension prior to the operation. Subsequently, the intravenous medications were substituted with oral antihypertensive drugs, such as beta-blockers, angiotensin-converting enzyme inhibitors, angiotensin receptor blockers, calcium

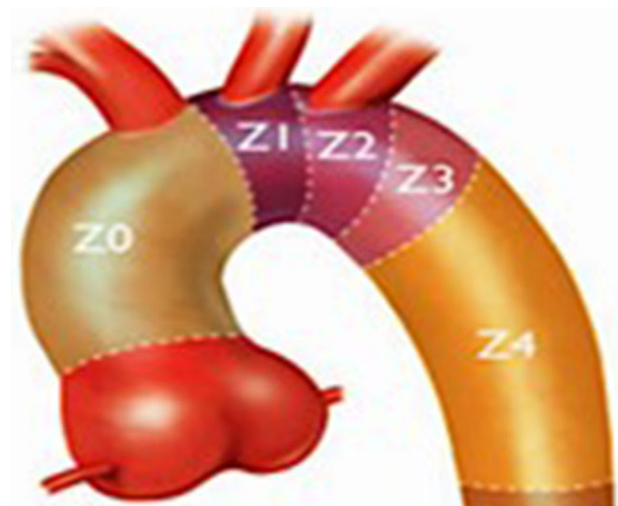
channel blockers, and diuretics, either independently or in conjunction. Medications were adjusted to maintain target systolic blood pressure at or below 120 mmHg during in-hospital monitoring and postdischarge follow-ups. Target blood pressure values were achieved at the time of patient discharge, and patients were consistently monitored at target levels during the follow-up periods. The decision on when, whether, and how to administer oral antihypertensive medications was left to the discretion of the treating physician, in accordance with prevailing guidelines and optimal clinical practices.

### Study endpoints and follow-up

Transthoracic echocardiography measurements were compared before and after the procedures. Aortic valve structure (bicuspid/tricuspid), aortic regurgitation, left ventricular end-diastolic diameter (LVEDD), left ventricular ejection fraction (LVEF), interventricular septum (IVS) and ascending aortic diameter were measured. Follow-up visits were scheduled at one week and one month, and subsequently, every three months, during which medical treatments were adjusted, and patients were counseled on their lifestyle modifications.

### Statistical analysis

The data were analyzed using IBM SPSS version 25.0 software (IBM Corp., Armonk, NY, USA) and MedCalc version 15.8 (MedCalc Software bvba, Ostend, Belgium). Descriptive statistical methods (frequency, percentage, mean, standard



**Figure 1.** Ishimura zones.

**Table 1**  
The demographic data of the patients

	n	%	Mean±SD	Median	Min-Max
Age (year)			61±12.8	62	27-85
Sex					
Female	5	15.6			
Male	27	84.4			
Comorbidities					
Diabetes mellitus	19	59.3			
Coronary artery disease	2	6.25			
Smoking	11	34.3			
Chronic obstructive pulmonary disease	3	9.3			
Hypertension	24	75			
Hyperlipidemia	18	56.25			

SD: Standard deviation.

**Table 2**  
Comparison of preoperative and postoperative echocardiographic data

	Preoperative			Postoperative			<i>p</i>
	Mean±SD	Median	Min-Max	Mean±SD	Median	Min-Max	
Aortic regurgitation	0.91±0.86			0.81±0.74			0.184*
Ascending aorta	3.83±0.45			3.81±0.45			0.557*
Interventricular septum	1.23±0.19			1.27±0.21			0.041*
LVEDD	4.89±0.49			4.83±0.44			0.291*
LVEF		60.00	20.00-66.00		55.00	20.00-60.00	0.010‡

\* Paired Samples t test; ‡ Wilcoxon Signed Ranks test; LVEDD: Left ventricular end-diastolic diameter; LVEF: Left ventricular ejection fraction.

deviation, median, and min-max) were used during the evaluation of the data. The distribution of the data was evaluated through the Shapiro-Wilk test, skewness and kurtosis measures, and graphical methods (histogram, Q-Q Plot, stem and leaf, and boxplot). For the comparison of pre- and postoperative values, a paired samples t-test was applied to normally distributed data, while the Wilcoxon signed-rank test was used for nonnormally distributed data. The statistical significance level was accepted as  $p < 0.05$ .

## RESULTS

Baseline demographic and clinical characteristics of the patients are shown in Table 1. The aortic valve was bicuspid in one (3.1%) patient and tricuspid in other patients. All patients were treated with a single endograft, and zone 3 TEVAR was the proximal landing zone in all patients. A comparison

of pre- and post-TEVAR echocardiography data was reported in Table 2. The mean follow-up period was  $23.7 \pm 8.4$  months. There was a significant increase in IVS measurements ( $p = 0.041$ ). In addition, a significant decrease was observed in the comparison of LVEF values ( $p = 0.01$ ). Ascending aortic diameter and LVEDD data, as well as valvular regurgitations at the aortic valves, were similar before and after the procedure.

## DISCUSSION

The goal of the present study was to elucidate the effects of TEVAR-induced aortic stiffening on LVEF and other cardiac remodeling parameters. It is known that from the origin of the left subclavian artery, mobility and compliance decrease towards the descending aorta and infrarenal aorta. Therefore, in patients with TAA, cases in which the proximal landing zone was zone 3 were selected, and this zone

was thought to be the most influencing area for aortic stiffness as it is the closest zone to the aortic arch.

The elastic structure of the aorta plays a critical role in hemodynamic adaptation.<sup>[5]</sup> However, the elastic properties of the aorta diminish with age or the presence of risk factors, such as smoking, hypertension, hyperlipidemia, and atherosclerosis. Apart from these factors, stiffening of the aortic wall after TEVAR due to the endograft structure affects cardiac remodeling. Some studies involving animal experiments have indicated clinical conditions such as tachycardia, hypertension, and reduced coronary perfusion in the early period after TEVAR.<sup>[9]</sup> However, in our patient group, these clinical findings were not observed in the early period. No early cardiac or adverse hemodynamic events were detected in any of the patients. In a report published by Kreibich et al.,<sup>[13]</sup> the impact of TEVAR on cardiac remodeling for aortic aneurysms was investigated in a cohort of 31 patients, revealing a decline in biventricular functions. Additionally, the research highlighted a decrease in TAPSE (tricuspid annular plane systolic excursion) and LVEF within the study group. In our study, we evaluated the left ventricular functions using LVEF measurements, and similarly, we observed a statistically significant reduction in LVEF ( $p=0.01$ ) during the postoperative follow-up period. Furthermore, a notable increase in IVS thickness, a parameter utilized for assessing left ventricular mass ( $p=0.041$ ), was also evident. This situation may indicate a subclinical coronary perfusion reduction that manifested as an effect over time.

Sincos et al.<sup>[14]</sup> reported in a histologic and immunohistochemical study the structural deterioration of the aortic wall after implantation of an endograft, with decreased amounts of muscle and elastic fibers. Halloran et al.<sup>[15]</sup> demonstrated that collagen and elastin content relative to the luminal surface area decrease with distance from the heart. Therefore, we may conclude that TEVAR procedures pose a higher risk of arterial stiffness compared to infrarenal abdominal aortic cases. These differences likely affect the compliance and structural integrity of the aorta.

Not only the decrease of mobility of the aortic arch but the oversizing of the endograft is one of the factors influencing the arterial stiffness. In patients with blunt thoracic aortic injury, particularly those who are younger and nonatherosclerotic aortas with smaller diameters, it is recommended that oversizing should not exceed 10%, as do the type B aortic

dissections. Notably, after endovascular repair, there is an observed loss of elasticity in the aortic wall regardless of the degree of oversizing. Based on the best available evidence, the current standard of 10 to 20% of oversizing, depending on the aortic pathology, appears to be safe and preferable.<sup>[16,17]</sup>

In 2018, van Bakel et al.<sup>[18]</sup> examined cardiac remodeling based on preoperative and postoperative data of eight patients who underwent TEVAR for TAAs. A significant increase in left ventricular mass index due to afterload increase was observed. In the same study, the preoperative and postoperative antihypertensive drug regimens of the patients were evaluated. Prior to TEVAR, 25 patients were receiving antihypertensive treatment, while after the procedure, antihypertensive drugs were prescribed to all 31 patients. Patients were administered dual ( $p=0.75$ ) or triple ( $p=0.33$ ) antihypertensive drug therapy after TEVAR. Beta-blockers and calcium channel blockers were the most commonly used medications.<sup>[18]</sup> During the follow-up, dual antihypertensive medication was initiated for treatment in our study cohort. Among those not achieving the target blood pressure range during follow-ups, triple antihypertensive therapy was prescribed for eight (25%) patients. In dual therapy, beta-blockers and angiotensin-converting enzyme inhibitors/angiotensin receptor blockers were preferred. For patients requiring triple therapy, calcium channel blockers were added to the treatment regimen.

Reducing aortic stiffness will contribute to the long-term preservation of the left ventricle and a decrease in hypertensive-related adverse cardiac effects. With an appropriate antihypertensive treatment plan aiming to lower afterload, it is likely that the heart can be protected through this mechanism in the long term. According to our research, medical device producers ought to create more compliant endografts to mitigate the mismatch between the device and aorta. To further manage blood pressure following TEVAR, extensive antihypertensive medication is required.

There are some limitations to this study. The number of patients included in this study is relatively small, as the majority of patients who were treated at our center were excluded. Due to the retrospective design of the study, we could only compare routine measurements, such as LVEF, LVEDD, and IVS diameter, during preoperative

preparation and postoperative follow-up. However, more valuable parameters, such as left ventricular mass index, LVPWd (left ventricular posterior wall end-diastole), and TAPSE, could be investigated to assess cardiac remodeling. Since echocardiogram dates were randomly determined, we could not provide information about the change processes. However, at the end of the follow-up period, there was a statistical change in both LVEF and IVS.

In conclusion, endovascular aortic procedures increase aortic stiffness, while open surgical repair does not. Therefore, lifelong follow-up should be mandatory to evaluate the aortic disease progression or endovascular complications, as well as related cardiovascular outcomes. For more accurate results, prospective studies involving large cohorts are necessary. Despite our evaluation being conducted in a limited patient population, our findings suggest that the stiffening of the aortic structure after TEVAR has a negative impact on cardiac remodeling. Consequently, it is imperative to explore new and more flexible designs for thoracic endograft structures. Careful adjustment of medical treatment may warrant the addition of medications that reduce afterload for patients.

**Ethics Committee Approval:** The study protocol was approved by the Ankara Bilkent City Hospital Ethics Committee (date: 01.12.2021, no: E1-21-2184). The study was conducted in accordance with the principles of the Declaration of Helsinki.

**Patient Consent for Publication:** A written informed consent was obtained from each patient.

**Data Sharing Statement:** The data that support the findings of this study are available from the corresponding author upon reasonable request.

**Author Contributions:** All authors contributed equally to the article.

**Conflict of Interest:** The authors declared no conflicts of interest with respect to the authorship and/or publication of this article.

**Funding:** The authors received no financial support for the research and/or authorship of this article.

## REFERENCES

- Harky A, Kai Chan JS, Ming Wong CH, Bashir M. Open versus endovascular repair of descending thoracic aortic aneurysm disease: A systematic review and meta-analysis. *Ann Vasc Surg* 2019;54:304-315.e5. doi: 10.1016/j.avsg.2018.05.043.
- Duvan İ, Sürer S, Şenkal AM, İnce İ, Kızıltepe U. Endovascular solution in a complex post-dissectional thoracic aortic aneurysm case. *Turk Gogus Kalp Dama* 2021;29:536-41. doi: 10.5606/tgkdc.dergisi.2021.21513.
- Posacıoğlu H, Parıldar M. Endovascular treatment of thoracic aortic aneurysms. *Turk Gogus Kalp Dama* 2011;19 (Suppl 2):33-40.
- Humphrey JD, Harrison DG, Figueroa CA, Lacolley P, Laurent S. Central artery stiffness in hypertension and aging: A problem with cause and consequence. *Circ Res* 2016;118:379-81. doi: 10.1161/CIRCRESAHA.115.307722.
- Redheuil A, Wu CO, Kachenoura N, Ohyama Y, Yan RT, Bertoni AG, et al. Proximal aortic distensibility is an independent predictor of all-cause mortality and incident CV events: The MESA study. *J Am Coll Cardiol* 2014;64:2619-29. doi: 10.1016/j.jacc.2014.09.060.
- Bissacco D, Conti M, Domanin M, Bianchi D, Scudeller L, Mandigers TJ, et al. Modifications in aortic stiffness after endovascular or open aortic repair: A systematic review and meta-analysis. *Eur J Vasc Endovasc Surg* 2022;63:567-77. doi: 10.1016/j.ejvs.2022.01.008.
- Papakonstantinou K, Rorris FP, Schizas N, Antonopoulos C, Samiotis I, Patris V, et al. Echocardiographic changes in cardiac function after thoracic endovascular aortic repair: A systematic review and meta-analysis. *Ann Vasc Surg* 2023;90:119-27. doi: 10.1016/j.avsg.2022.10.011.
- Moulakakis KG, Kadoglou NPE, Antonopoulos CN, Mylonas SN, Kakisis J, Papadakis I, et al. Changes in arterial stiffness and N-terminal pro-brain natriuretic peptide levels after endovascular repair of descending thoracic aorta. *Ann Vasc Surg* 2017;38:220-6. doi: 10.1016/j.avsg.2016.04.025.
- Zacharoulis AA, Arapi SM, Lazaros GA, Karavidas AI, Zacharoulis AA. Changes in coronary flow reserve following stent implantation in the swine descending thoracic aorta. *J Endovasc Ther* 2007;14:544-50. doi: 10.1177/152660280701400417.
- Tzilalis VD, Kamvysis D, Panagou P, Kaskarelis I, Lazarides MK, Perdikides T, et al. Increased pulse wave velocity and arterial hypertension in young patients with thoracic aortic endografts. *Ann Vasc Surg* 2012;26:462-7. doi: 10.1016/j.avsg.2011.06.021.
- Gökkurt Y, Yürekli İ, Çakır H, İner H, Yeşilkaya N, Karaağaç E, et al. Mid- and long-term results in patients with thoracic endovascular aortic repair. *Cardiovasc Surg Int* 2021;8:103-8. doi: 10.5606/e-cvsi.2021.1141.
- Yiğit G, Akkaya BB, Mungan U, Erdoğan KE, Hasanzade S, Sağlam MS, et al. Influence of sex after elective thoracic endovascular aortic repair. *Turk J Vasc Surg* 2021;30:199-205. doi: 10.9739/tjvs.2021.1081.
- Kreibich M, Morlock J, Beyersdorf F, Berger T, Allweier S, Kondov S, et al. Decreased biventricular function following thoracic endovascular aortic repair. *Interact Cardiovasc Thorac Surg* 2020;30:600-4. doi: 10.1093/icvts/ivz298.
- Sincos IR, da Silva ES, Belczak SQ, Baptista Sincos AP, de Lourdes Higuchi M, Gornati V, et al. Histologic analysis of stent graft oversizing in the thoracic aorta. *J Vasc Surg* 2013;58:1644-1651.e4. doi: 10.1016/j.jvs.2013.02.005.

15. Halloran BG, Davis VA, McManus BM, Lynch TG, Baxter BT. Localization of aortic disease is associated with intrinsic differences in aortic structure. *J Surg Res* 1995;59:17-22. doi: 10.1006/jsre.1995.1126.
16. Askin G, Mola S, Aytakin B, Hasanzade S, Tumer NB, Mavioglu HL, et al. Endovascular therapy in blunt traumatic aortic injuries. *Turk J Vasc Surg* 2022;31:157-62. doi: 10.9739/tjvs.2022.09.017
17. Yigit G, Deniz G, Hasanzade S, Gevrek M, Celikten AE, Tumer NB, et al. Early and mid-term results of endovascular repair for type B aortic dissections: A single tertiary center experience. *Turk J Vasc Surg* 2023;32:127-32. doi: 10.9739/tjvs.2023.07.019.
18. van Bakel TMJ, Arthurs CJ, Nauta FJH, Eagle KA, van Herwaarden JA, Moll FL, et al. Cardiac remodelling following thoracic endovascular aortic repair for descending aortic aneurysms. *Eur J Cardiothorac Surg* 2019;55:1061-70. doi: 10.1093/ejcts/ezy399.