

An image of single coronary artery in a four-month-old child undergoing ventricular septal defect repair surgery

Mehmet Taşar¹, Zeynep Eyiletten², Adnan Uysalel²

Received: June 15, 2015 Accepted: January 01, 2016 Published online: March 03, 2016

Single coronary artery is an extremely rare congenital anomaly in which there is only one coronary artery arising from the aorta by a single ostium, giving branches. Since these anomalies are usually asymptomatic, interventions are limited.^[1,2]

A four-month-old child underwent surgery for an 8 mm isolated perimembranous ventricular septal defect. He also had coronary artery origin anomaly detected by catheterization preoperatively (Figure 1). Preoperative evaluation showed no other pathology (Figure 2). All coronary branches were given by the single coronary artery without any kinking or compression (Figure 3). A written informed consent was obtained from the patient and ventricular septal defect was repaired. The operation was completed successfully.

A single coronary artery is a rare coronary artery origin anomaly which can be often associated with other congenital cardiac defects, such as ventricular septal defect. This anomaly is usually in benign nature and seldomly requires surgical intervention.

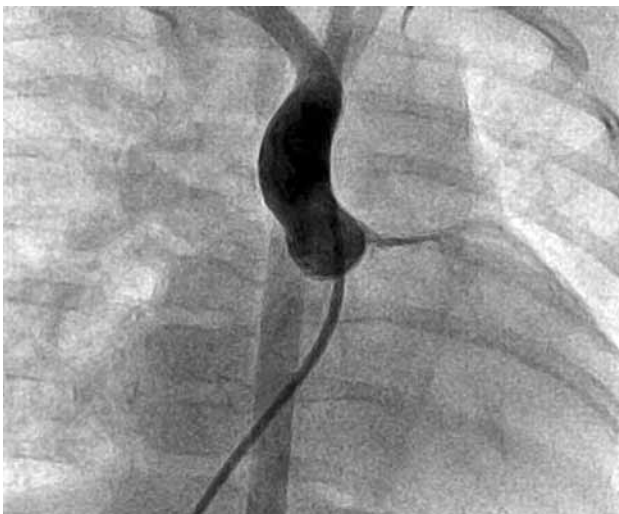

Figure 1. Preoperative angiography showing a single coronary artery.

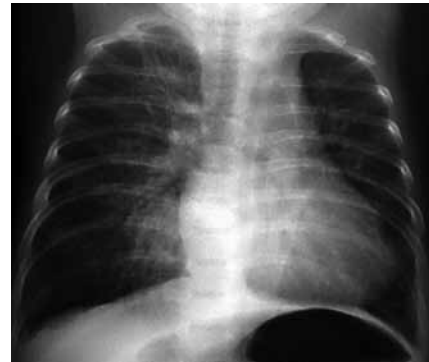

Figure 2. Preoperative radiography shows cardiomegaly.

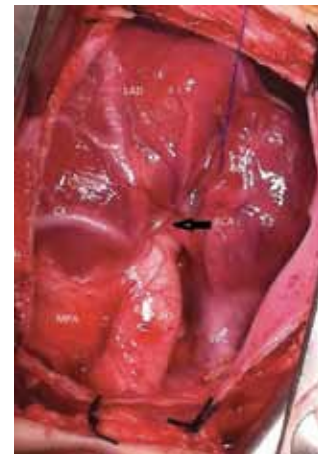


Figure 3. An intraoperative view of the single coronary artery and its coronary branches.

LAD: Left anterior descending; RCA: Right coronary artery; CX: Circumflex; AO: Aorta; MPA: Main pulmonary artery; SVC: Superior vena cava.

¹Department of Pediatric Cardiovascular Surgery, Dr Sami Ulus Maternity and Children Health and Diseases Training and Research Hospital, Ankara, Turkey

²Department of Pediatric Cardiovascular Surgery, Medical Faculty of Ankara University, Ankara, Turkey

Corresponding author: Mehmet Taşar, MD. Dr. Sami Ulus Kadın Doğum Çocuk Sağlığı ve Hastalıkları Eğitim ve Araştırma Hastanesi, Pediatrik Kalp Damar Cerrahisi Kliniği, 06080 Altındağ, Ankara, Turkey.

Tel: +90 312 - 595 71 59 e-mail: mehmet.tasar@hotmail.com

Declaration of conflicting interests

The authors declared no conflicts of interest with respect to the authorship and/or publication of this article.

Funding

The authors received no financial support for the research and/or authorship of this article.

REFERENCES

1. Vural A, Aksoy H, Karagöz A, Dindar B. Successful primary coronary angioplasty for acute inferior myocardial infarction in a patient with RII-type single coronary artery. *BMJ Case Rep* 2015;2015.
2. Aubry P, Amami M, Halna du Fretay X, Dupouy P, Godin M, Juliard JM. Single coronary ostium: single coronary artery and ectopic coronary artery connected with the contralateral artery. How and why differentiating them?. *Ann Cardiol Angeiol (Paris)* 2013;62:404-10. [Abstract]