

## Treatment of catheter entrapment during transradial approach in a patient with vasospastic angina

Ertuğrul Zencirci<sup>1</sup>, Aleks Değirmencioğlu<sup>1</sup>, Ayca Eren Zencirci<sup>2</sup>, Gültekin Karakuş<sup>1</sup>, Ahmet Akyol<sup>1</sup>

Received: March 25, 2015 Accepted: May 15, 2015 Published online: August 03, 2015

### ABSTRACT

In this report, we present a 27-year-old male patient who was scheduled for an urgent left heart catheterization due to resting angina pectoris with ST segment elevation in anterior precordial leads. Catheter entrapment occurred due to severe vasospasm of radial artery during transradial coronary angiography which showed coronary spasm treated with intracoronary nitroglycerin. Reversal of severe vasospasm and release of entrapped catheter were unable to be achieved until forearm heating. This case report is presented to demonstrate that forearm heating may effectively reverse severe and resistant vasospasm of radial artery during a transradial intervention in patients with vasospastic angina.

**Keywords:** Heating; transradial approach; vasospastic angina.

Transradial approach has become increasingly popular and has been shown to decrease the incidence of access-site complications compared to the transfemoral approach.<sup>[1]</sup> Most of the previous studies revealed the risk factors and management of radial artery spasm, which is the most frequent complication during transradial approach.<sup>[2,3]</sup> However; radial artery spasm-related catheter entrapment during transradial cardiovascular interventions is extremely rare and its management has not been precisely defined.

### CASE REPORT

A 27-year-old man was admitted to our emergency department with resting angina pectoris. He was a heavy smoker. Twelve-lead electrocardiography (ECG) showed, ST segment elevation in the anterior precordial leads. His physical examination findings were non-specific. His height was 172 cm and with a weight of 75 kg. He was scheduled for an urgent left heart catheterization. A 6F-short (7 cm) hydrophilic sheath Radiofocus Introducer II (Terumo, Tokyo, Japan) was introduced into the right radial artery. Nitroglycerin 200 µg and heparin 5,000 U were injected through the side port of the sheath. Guiding 6F left Judkins catheter (Launcher, Medtronic, Minneapolis, USA) was inserted through the sheath to the aortic root over a hydrophilic guidewire without any difficulty. The left coronary angiography demonstrated left anterior descending coronary artery

spasm causing %90 narrowing of the luminal diameter. After intracoronary injection of nitroglycerin 200 µg, coronary spasm was relieved and it was considered as vasospastic angina (Figure 1).

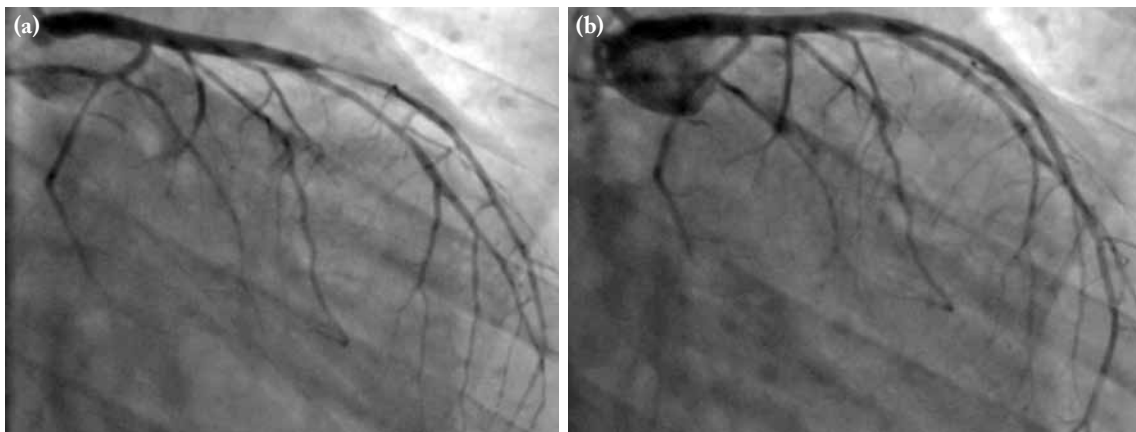
During removal of the guiding catheter, the patient suffered from severe right forearm pain distal to antecubital fossa. Further manipulation of the catheter was not possible. On fluoroscopy, the catheter was not looped or kinked. Severe vasospasm of radial artery was thought to cause catheter entrapment. Intravenous verapamil 5 mg waiting and re-trying, nitroglycerin infusion, and midazolam 2 mg all failed. After forearm heating by Warm Touch, model WT-5300 A convective air patient warming system (Covidien, Mansfield, USA), we removed the catheter without any difficulty. Finally, we performed a forearm angiography which showed mild vasospasm of radial artery persisting after catheter removal (Figure 2). Following the removal of the sheath, an inflatable hemostasis device was introduced. Radial artery was found to be patent the day after the procedure. The patient was free of angina throughout a six-month follow-up period.

<sup>1</sup>Department of Cardiology, Acıbadem Maslak Hospital, İstanbul, Turkey

<sup>2</sup>Department of Cardiology, Siyami Ersek Cardiovascular and Thoracic Surgery Training and Research Hospital, İstanbul, Turkey

**Corresponding author:** Ertuğrul Zencirci, M.D. Acıbadem Maslak Hastanesi, Kardiyoloji Bölümü, 34457 Maslak, İstanbul, Turkey.

Tel: +90 212 - 204 43 62 e-mail: ertuzencirci@gmail.com



**Figure 1.** (a) Left coronary angiography image showing the left anterior descending coronary artery spasm causing 90% narrowing of the luminal diameter in the right caudal projection. (b) After intracoronary nitroglycerin injection, coronary spasm was relieved.

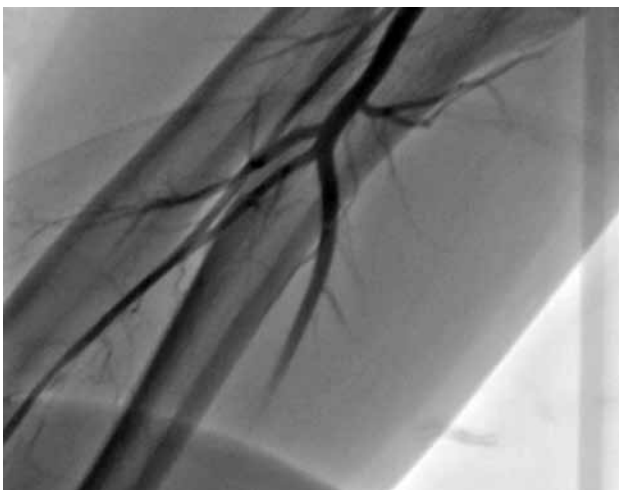
## DISCUSSION

This case described the successful treatment of catheter entrapment due to severe radial artery spasm that accompanies vasospastic angina with a simple and effective non-pharmacological technique. Radial artery is mainly composed of smooth muscle cells together with alpha-adrenoceptor-predominance which explains the specific susceptibility to vasospasm.<sup>[4]</sup> Circulating catecholamines mainly activate alpha-1-adrenoceptor. Patient-related factors such as small size and anomalous origin of the radial artery, female sex, younger age, short stature, and anxiety were defined as predisposing factors for radial artery spasm during transradial

approach.<sup>[3]</sup> In the present report, our case was young and suffered from anxiety. The majority of previous reports advocated nitrate derivative or verapamil to prevent spasm of radial artery; however, there is currently no consensus on the optimal agents.<sup>[3]</sup> As in our case, we use intra-arterial nitroglycerin for such patients on a regular basis.

In addition, heating has been shown to be a stimulus evoking the conduit artery dilatation. Previously, it has been demonstrated that heating may induce radial artery vasodilation through the flow-mediated dilatation.<sup>[5,6]</sup> Increased local temperature has been also documented to modulate alpha-1-adrenergic receptor-mediated vasoconstriction by increasing the release of endothelial cell-derived vasodilators.

Moreover, several studies have suggested hyperreactivity to adrenergic stimulation triggering coronary artery spasm in patients with vasospastic angina. Type A behavior pattern, severe anxiety and panic disorders were described as some of the predisposing factors for vasospastic angina. Previous studies have suggested that vasospastic angina is associated with migraine and Raynaud phenomenon.<sup>[7,8]</sup> These observations have stimulated the hypothesis that some of the patients with vasospastic angina have generalized vasospastic disorder.<sup>[7,8]</sup> The predisposing factors and hyperreactivity to adrenergic stimulation may account for the common underlying mechanism for vasospastic angina and radial artery spasm. Radial artery spasm may be also considered as a part



**Figure 2.** Recent forearm angiography image visualizing mild vasospasm of the radial artery following catheter removal.

of the clinical presentation of generalized arterial vasospasm. However, definitive evidences supporting such an association are not available. As it may be a coincidental catheter-induced radial artery spasm. Further studies are warranted to establish a conclusion.

In conclusion, we suggest that forearm heating may effectively reverse severe and pharmaco-resistant vasospasm of radial artery during a transradial intervention in patients with vasospastic angina.

### Acknowledgement

We would like to thank Osman Konencoglu, catheterization lab technician for his contribution to the present report.

### Declaration of conflicting interests

The authors declared no conflicts of interest with respect to the authorship and/or publication of this article.

### Funding

The authors received no financial support for the research and/or authorship of this article.

---

## REFERENCES

---

1. Jolly SS, Amlani S, Hamon M, Yusuf S, Mehta SR. Radial versus femoral access for coronary angiography or intervention and the impact on major bleeding and ischemic events: a systematic review and meta-analysis of randomized trials. *Am Heart J* 2009;157:132-40.
2. Kiemeneij F, Vajifdar BU, Eccleshall SC, Laarman G, Slagboom T, van der Wieken R. Evaluation of a spasmolytic cocktail to prevent radial artery spasm during coronary procedures. *Catheter Cardiovasc Interv* 2003;58:281-4.
3. Ho HH, Jafary FH, Ong PJ. Radial artery spasm during transradial cardiac catheterization and percutaneous coronary intervention: incidence, predisposing factors, prevention, and management. *Cardiovasc Revasc Med* 2012;13:193-5.
4. He GW, Yang CQ. Characteristics of adrenoceptors in the human radial artery: clinical implications. *J Thorac Cardiovasc Surg* 1998;115:1136-41.
5. Joannides R, Costentin A, Iacob M, Compagnon P, Lahary A, Thuillez C. Influence of vascular dimension on gender difference in flow-dependent dilatation of peripheral conduit arteries. *Am J Physiol Heart Circ Physiol* 2002;282:H1262-9.
6. Bellien J, Thuillez C, Joannides R. Role of endothelium-derived hyperpolarizing factor in the regulation of radial artery basal diameter and endothelium-dependent dilatation in vivo. *Clin Exp Pharmacol Physiol* 2008;35:494-7.
7. Wayne VS. A possible relationship between migraine and coronary artery spasm. *Aust N Z J Med* 1986;16:708-10.
8. Miller D, Waters DD, Warnica W, Szlachcic J, Kreeft J, Th eroux P. Is variant angina the coronary manifestation of a generalized vasospastic disorder? *N Engl J Med* 1981;304:763-6.