

Histopathological findings of an excised varicose vein complicated with chemical phlebitis

Seyhan Yılmaz,¹ Eray Aksoy,¹ Güven Güney²

Received: March 05, 2014 Accepted: June 23, 2014

Sclerotherapy aims to obliterate the varicose veins after injection of the sclerosing substance into vein lumen by causing stenosis, fibrosis and thrombosis through endothelial cell damage, spasm and inflammatory reaction mechanisms. However, there is a limited number of studies investigating the histopathological effects of sclerotherapy to the human veins. In this case report, we evaluated the histopathological results of the *in vivo* liquid sclerotherapy [Lauromacrogol 400 (40 mg-2% Aethoxysklerol)] on a vein wall specimen surgically excised after development of a painful and non-resorbing thrombus.

Keywords: Local anesthesia; sclerotherapy; varicose vein.

Minimally invasive techniques in varicose vein treatment have gained an increased popularity thanks to their satisfactory outcomes, low complication rates and faster return to normal activities.^[1] Physical and chemical methods are available to obliterate the lumen of varicose veins and sclerotherapy is one of the chemical methods being used over the last 60 years.^[2] Sclerosing substance may cause stenosis, fibrosis and permanent thrombosis through endothelial cell damage, spasm, and inflammatory reaction mechanisms to obliterate varicose veins. Data regarding *in vivo* histopathological findings after sclerotherapy is also limited.

In this case report, we evaluated the histopathological results of the *in vivo* liquid sclerotherapy [Lauromacrogol 400 (40 mg-2% Aethoxysklerol)] on a vein wall specimen surgically excised after development of a painful and non-resorbing thrombus.

CASE REPORT

A 32-year-old woman who received liquid sclerotherapy for calf varicose veins three months ago presented with a painful phlebitis at the area of injection. Her complaints began about two months after receiving sclerotherapy. She had no previous history of chronic comorbidities, steroid or oral contraceptive use, having hypercoagulation disease or allergies. She had a history of 10 pack-year smoking. The patient's CEAP classification (the Clinical-Etiology-Anatomy-Pathophysiology) was varicose

veins (C₂), primary (Ep), superficial (As), reflux (Pr). According to the information from hospital registry and patient's statement, she received our standard protocol of practice: 2 ml of lauromacrogol 2% was injected into the vessel without diluting, a 32 G needle was used, the area of injection was compressed for several minutes, the leg was bandaged, and the patient was discharged with resting instructions. Although she used topical anti-inflammatory agents for three months, the pain and stiffness over the phlebitis varicosity were not relieved. The patient requested removal of the diseased varicose vein. Physical examination revealed 4 cm in length and 6 mm in width hyperpigmented lesion on the diseased vessel segmented, which was firm and tender with palpation. Duplex ultrasound scanning showed thrombus formation in formerly treated varicose veins. Under local anesthesia, a 3 cm long diseased segment of the vein was ligated at both ends and excised between the tied ends. The specimen was fixed in normal saline solution and stained with hematoxylin and eosin for histopathological examination. Histopathological findings were as follows: vascular lumen was almost totally obliterated

Departments of ¹Cardiovascular Surgery, ²Pathology, Hitit University Çorum Training and Research Hospital, Çorum, Turkey

Corresponding author: Seyhan Yılmaz, M.D. Hitit Üniversitesi Çorum Eğitim ve Araştırma Hastanesi Kalp ve Damar Cerrahisi Kliniği, 19200 Yeniyol, Çorum, Turkey.

Tel: +90 364 - 223 03 23 e-mail: drlabarna@gmail.com

by a well-organized and partly recanalized thrombus; tunica media had decreased in thickness, and the endothelium was eroded in focal sectional areas; and tunica intima was lacking in sites where thrombus was adherent. There were also extensive involvement with neutrophil leukocytes, lymphocytes and degenerated smooth muscle cells (Figure 1). The patient was discharged and postoperative course was uneventful (The patient presented herein did not allow us to use a photograph of the lesion before the operation, however, she gave consent to have her information used for scientific publishing).

DISCUSSION

Sclerosing agents not only results embolization of the target vein, but also disrupt its endothelium limiting proliferation and collateralization.^[3] Although earlier studies suggested that hypertonic solutions might cause fewer side effects (i.e. hyperpigmentation) than chemical agents,^[4] recent data suggests that sclerosing agents are superior to placebo in terms of efficacy and patient satisfaction.^[5] A recent prospective randomized study showed no superiority of hypertonic saline solution over polidocanol and also a higher rate of pain during its injection.^[6] Currently, sclerotherapy with sclerosing agents is regarded as the choice of therapy in treating spider and reticular veins.^[7] According to a report from England, the number of patients requesting for sclerotherapy increased by 300% over seven years, although number of patients presenting with varicose veins declined by 34%.^[1]

Complications related to sclerotherapy are extremely rare^[2,8] and may not only be dependent on

chemical irritation or iatrogenic factors; however, they also be related with patients related factors such as hypercoagulable state.^[9] There have been a number of case reports in the past about development of sclerotherapy-related severe life threatening complications including acute ischemic stroke in a 73-year-old woman,^[10] myocardial infarction in a 61-year-old patient with foramen ovale,^[11] arterial occlusion due to intra-arterial injection in a 59-year-old woman,^[12] middle cerebral arterial embolism,^[13] and visual loss in a 66-year-old woman.^[14] It is likely that foam sclerotherapy in elderly may rarely cause serious complications, while related complications are usually mild, transient and underreported.

Our histopathological assessment supports the concept that sclerosing agent not only resulted in thrombus formation within the vein lumen, but also induced a substantial structural damage to the vessel wall. We observed that vein endothelium was irreversibly eroded and tunica media was almost completely disappeared in focal sectional areas. Such changes should be regarded as the natural consequence of the treatment. Presence of both inflammatory and necrotic cells in histopathological specimen is likely to explain why the patient has been suffering from pain and sensitivity despite using topical medications. Our patient had no further complications such as ascending thrombophlebitis which occurred previously in a 48-year-old patient undergoing foam sclerotherapy. The authors reported that the patient presented with some symptoms similar to ours after receiving foam sclerotherapy for varicose veins at lower extremity. That patient was eventually diagnosed with breast cancer.^[15]

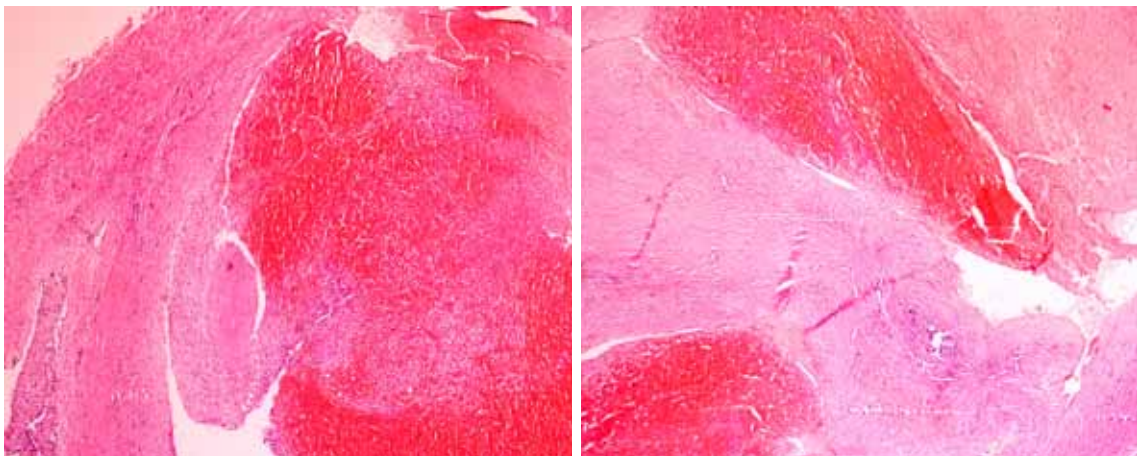


Figure 1. Photomicrograph of the sectional areas from excised vein sample material (H-E x 40).

Declaration of conflicting interests

The authors declared no conflicts of interest with respect to the authorship and/or publication of this article.

Funding

The authors received no financial support for the research and/or authorship of this article.

REFERENCES

1. Kanwar A, Hansrani M, Lees T, Stansby G. Trends in varicose vein therapy in England: radical changes in the last decade. *Ann R Coll Surg Engl* 2010;92:341-6.
2. Kern P. Sclerotherapy of varicose leg veins. Technique, indications and complications. *Int Angiol* 2002;21(2 Suppl 1):40-5.
3. Albanese G, Kondo KL. Pharmacology of sclerotherapy. *Semin Intervent Radiol* 2010;27:391-9.
4. Weiss RA, Weiss MA. Incidence of side effects in the treatment of telangiectasias by compression sclerotherapy: hypertonic saline vs. polidocanol. *J Dermatol Surg Oncol* 1990;16:800-4.
5. Schwartz L, Maxwell H. Sclerotherapy for lower limb telangiectasias. *Cochrane Database Syst Rev* 2011;12:CD008826.
6. Peterson JD, Goldman MP, Weiss RA, Duffy DM, Fabi SG, Weiss MA, et al. Treatment of reticular and telangiectatic leg veins: double-blind, prospective comparative trial of polidocanol and hypertonic saline. *Dermatol Surg* 2012;38:1322-30.
7. Mann MW. Sclerotherapy: it is back and better. *Clin Plast Surg* 2011;38:475-87.
8. Bihari I. Injection sclerotherapy for varicosities of the lower limb: 25 years of experience with 115000 injections. *Orv Hetil* 2007;148:51-8.
9. Feied CF. Deep vein thrombosis: the risks of sclerotherapy in hypercoagulable states. *Semin Dermatol* 1993;12:135-49.
10. Adatia S, Nambiar V, Kapadia R, Abuzinath A, Apel S, Alqarni M, et al. Acute ischemic stroke caused by paradoxical air embolism following injection sclerotherapy for varicose veins. *Neurol India* 2013;61:431-3.
11. Snow TA, McEntee JP, Greaves SC, White HD. Myocardial infarction following sclerotherapy in a patient with a patent foramen ovale. *N Z Med J* 2012;125:64-7.
12. Hafner F, Froehlich H, Gary T, Brodmann M. Intra-arterial injection, a rare but serious complication of sclerotherapy. *Phlebology* 2013;28:64-73.
13. Asbjornsen CB, Rogers CD, Russell BL. Middle cerebral air embolism after foam sclerotherapy. *Phlebology* 2012;27:430-3.
14. Leong JC, Johnston NR. Visual loss following sclerotherapy for varicose veins. *BMJ Case Rep* 2011;2011.
15. Kobus S, Reich-Schupke S, Pindur L, Altmeyer P, Stucker M. Ascending thrombophlebitis after foam sclerotherapy as first symptom of breast cancer. *J Dtsch Dermatol Ges* 2009;7:239-40.