

## Giant pseudoaneurysm due to Dacron graft degeneration: A case report

Ayşegül Durmaz , Ali Arıkan , Muhip Kanko 

Department of Cardiovascular Surgery, Medicine Faculty of Kocaeli University, Kocaeli, Türkiye

Received: September 19, 2022 Accepted: November 10, 2022 Published online: March 27, 2023

### ABSTRACT

Knitted Dacron grafts are often preferred as they are easy to process, soft, and flexible; they also tend to expand due to their high porosity. Bleeding and pseudoaneurysm formation at the anastomotic site are common complications of vascular surgery, but nonanastomotic bleeding due to degeneration of Dacron graft's textile structure is rare. Here, we present a 70-year-old male diagnosed with a giant pseudoaneurysm that continues from the femoral artery to the popliteal artery formed due to the degeneration of the previous seven-year-old prosthetic graft. The pseudoaneurysm continued to be the source of arterial flow with its capsule, and the arterial flow into it was able to provide blood supply to the lower extremity without causing ischemia. The patient underwent surgery to excise the giant pseudoaneurysm and create a new bypass between the femoral and popliteal arteries. Today, the durability of prostheses is becoming increasingly important, and modifications in the manufacturing process have made Dacron grafts more resistant to cyclic pulsatile stretching and facilitated the adaptation of the prosthetic material to the host tissue. Despite all the remarkable innovations over the last 50 years, complications of prosthetic grafts can result in fatal bleeding. This situation emphasizes the importance of close follow-up and detailed clinical and radiological evaluation of patients.

**Keywords:** Dacron, graft degeneration, femoropopliteal bypass, peripheral artery disease, pseudoaneurysm.

In the surgical treatment of peripheral artery diseases, prosthetic graft materials are used when an autologous vein is unavailable. Although polyethylene terephthalate (Dacron) grafts are considered ideal arterial prosthetic grafts, some have been shown to have early or late complications.<sup>[1,2]</sup> Here, we present a case with a giant pseudoaneurysm formed along the former destroyed prosthetic graft, which continued to be the source of arterial flow throughout the popliteal artery (PA) in connection with the former femoropopliteal bypass graft operation. It was seen that the arterial flow in this giant pseudoaneurysm capsule could provide blood supply to the lower extremity without causing ischemia.

### CASE REPORT

A 70-year-old male who underwent a left femoropopliteal Dacron bypass for peripheral artery disease approximately seven years earlier was evaluated with intermittent claudication, swelling, and pain in the left groin. The patient's medical history was limited due to the inadequacy of the medical records of earlier hospitals. In the physical examination, a pulsatile mass approximately 6×8 cm in size was present in the left inguinal region. Distal pulses of the left lower

extremity were not palpable. Doppler ultrasonography revealed an 8×4 cm hematoma that spread into the muscle around the graft of the left superficial femoral artery (SFA). Examinations with angiography and computed tomography angiography were compatible with a short-necked aneurysm associated with the left SFA and a hematoma around the artery (Figure 1).

However, the surgical exploration of the graft site revealed a giant pseudoaneurysm caused by the degradation of the entire prosthesis. Since the pseudoaneurysm adhered to the venous structures posteriorly, only the fibrous capsule forming the anterior wall from the SFA to the PA could be excised. There was backflow from the distal portion of the PA. We observed that the previous graft material was Dacron and had begun to degenerate between native tissues but remained in pieces. There was no evidence

**Corresponding author:** Ayşegül Durmaz, MD. Kocaeli Üniversitesi Tıp Fakültesi Kalp ve Damar Cerrahisi Anabilim Dalı, 41001 Umuttepe, Kocaeli, Türkiye.  
E-mail: veyseltemizkan@yahoo.com

### Citation:

Durmaz A, Arıkan A, Kanko M. Giant pseudoaneurysm due to Dacron graft degeneration: A case report. *Cardiovasc Surg Int* 2023;10(1):63-67. doi: 10.5606/e-cvsi.2023.1416.

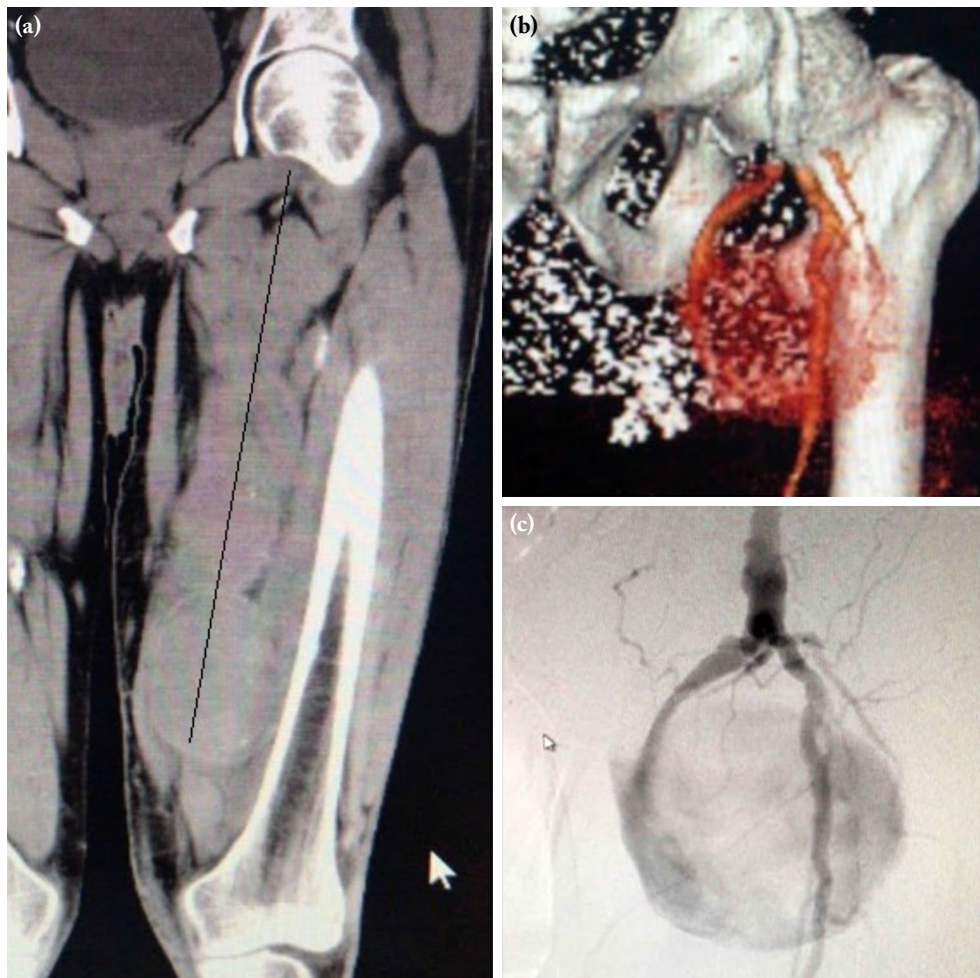
of an isolated defect in the tissues around the graft. Femoropopliteal bypass surgery between SFA and PA-above knee with reversed *in situ* great saphenous vein was performed. The postoperative course was uneventful the year following the surgery, and the patient was free of symptoms (Figure 2).

## DISCUSSION

Knitted Dacron grafts are easy to handle, soft, and pliable; however, they tend to dilate due to their high porosity. Knox<sup>[3]</sup> first reported structural deficiencies in prosthetic grafts in 1962. Bleeding or pseudoaneurysm formation at the anastomosis site is a common complication of Dacron grafts in vascular

surgery. However, nonanastomotic bleeding connected to the degeneration of the textile structure of the graft and the formation of such a giant pseudoaneurysm starting from the femoral artery and continuing to the PA is rare in the literature.<sup>[4]</sup> The early detection of a Dacron rupture is tricky due to the unpredictability of the time between the clinical manifestation. In our case, we believe the diagnosis was delayed for this reason.

Manufacturing flaws, such as excessive heating during yarn texturization, crimping by thermal fixation, excessive stretching of yarns during knitting, chemical cleaning, and gamma or beta ray sterilization are possible causes for the loss of structural integrity



**Figure 1.** Radiologic imaging of the giant pseudoaneurysm is the source of arterial flow with its capsule and continues from the femoral artery to the popliteal artery. **(a)** The computed tomography angiography (coronal view); **(b)** Angiographic image; **(c)** digital subtraction angiography (DSA) image.

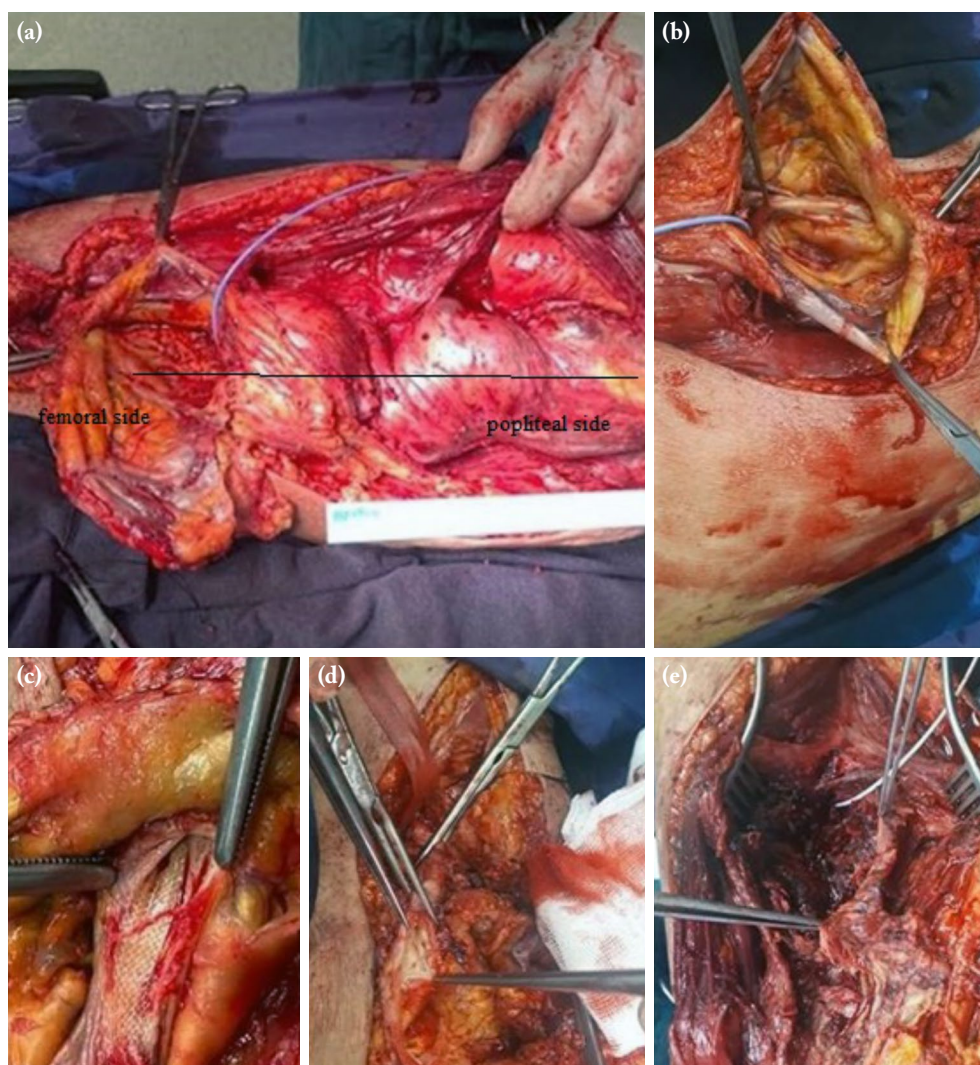
of a graft.<sup>[2,5]</sup> Generally, the graft fabrication process is standardized, computer-controlled, and extensive quality control measures are performed before the graft is marketed.<sup>[2]</sup> Intrinsic structural graft failure formations have been reported anywhere from 12 months to 19 years, with an estimated incidence of 0.5 to 3% in the earliest series (Figure 3).<sup>[1]</sup>

Some studies have reported giant cell reactions to fragmented Dacron fibers in the histological examination of the excised graft; however, they have not demonstrated an effective etiology or a predisposing factor.<sup>[1]</sup> In the histopathological examination,

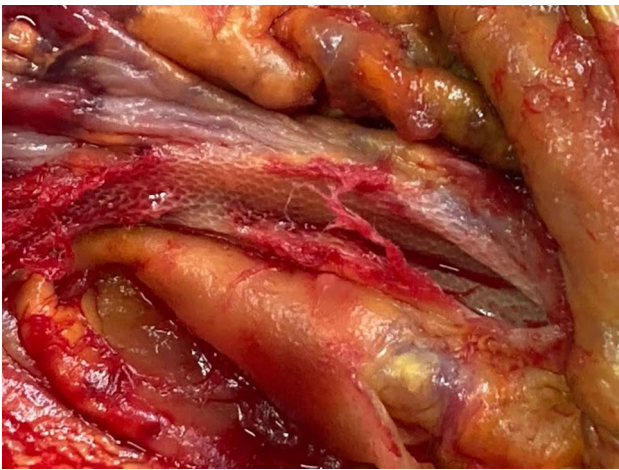
lymphocytic inflammatory infiltration was the only pathological finding involving inflammatory cells.

Graft infections in vascular surgery have the most severe complications, including anastomotic bleeding, sepsis, and death. The overall incidence of vascular graft infections is 1.5 to 2% in femoral grafts.<sup>[6]</sup> In our case, no infection was detected in both tissue and graft material.

In the present case, the late degeneration of the knitted Dacron fibers may have caused gradual stretching and focal disruption of the graft, resulting



**Figure 2.** Surgical exploration of the giant pseudoaneurysm, and the former Dacron graft degeneration. **(a)** Fibrous capsule of the pseudoaneurysm (outside view), **(b)** Fibrous capsule of the pseudoaneurysm (inside view), **(c)** Degeneration of the Dacron graft, **(d, e)** Separation in Dacron fibrils.



**Figure 3.** The degenerated Dacron graft with continued distal flow through the pseudoaneurysm capsule.

in a localized pseudoaneurysm that would subsequently enlarge.<sup>[7,8]</sup> Degradation may be related to many factors, such as designing the textile structure, fabrication flaws, modifications of the prosthesis during the manufacturing process or the surgery by inappropriate handling, unpadding clamps, or the surgeon's overstretching of the graft. There may have also been secondary physicochemical alterations due to chronic foreign body giant cell inflammatory reactions and mechanical fatigue caused by repeated bending and the constant systolic-diastolic arterial stresses.<sup>[4,9]</sup> Repetitive hydrodynamic microtraumas, as with pulsatile blood flow, cause progressive stretching and thinning of the yarn filaments due to cracking or gradual ruptures. The ends of these distorted, broken fibers appear tapered and frayed. Once this occurs, the load is transferred to the remaining neighboring filaments of the weave, resulting in torn fibers.<sup>[2]</sup> During the operation of this patient, we observed that the graft degenerated along its length, as if supporting the structural collapse.

Traditionally, aneurysms are treated by the excision of the disrupted graft and replacement with a new prosthetic graft.<sup>[7,8,10]</sup> In our case, we preferred an open surgical intervention for our patient's exploratory diagnosis and treatment.

This case study was not extensive. Graft degeneration should still be considered a late-term complication despite all the developments in the construction and inspection processes of Dacron grafts. No matter how much time has passed since the

operation, complications related to grafts should be kept in mind.

In conclusion, the ideal vascular prosthetic conduit should be easily accessible, resistant to dilatation and infections, stable, biocompatible, and longstanding, with a durability superior to the patient's life expectancy. They should also provide and sustain a thromboresistant flow surface and have elastic properties that ensure a normal artery's patency, compliance, and flexibility.

**Patient Consent for Publication:** Written informed consent was obtained from both the patient and a legally authorized representative of the patient for their anonymized information published in this article.

**Data Sharing Statement:** The data that support the findings of this study are available from the corresponding author upon reasonable request.

**Author Contributions:** Idea/concept: M.K.; Design, data collection and/or processing, literature review, writing the article: A.D.; control/supervision, critical review: A.A.

**Conflict of Interest:** The authors declared no conflicts of interest with respect to the authorship and/or publication of this article.

**Funding:** The authors received no financial support for the research and/or authorship of this article.

## REFERENCES

- Berger K, Sauvage LR. Late fiber deterioration in Dacron arterial grafts. *Ann Surg* 1981;193:477-91.
- Van Damme H, Deprez M, Creemers E, Limet R. Intrinsic structural failure of polyester (Dacron) vascular grafts. A general review. *Acta Chir Belg* 2005;105:249-55. doi: 10.1080/00015458.2005.11679712.
- Knox WG. Aneurysm occurring in a femoral artery Dacron prosthesis five and one-half years after insertion. *Ann Surg* 1962;156:827-30. doi: 10.1097/00000658-196211000-00018.
- Agostinucci A, Data S, Pagliasso E. Late non-anastomotic rupture of a bifurcated dacron aortic graft treated using a Gore Excluder limb endoprosthesis. *Vasc Specialist Int* 2019;35:241-4. doi: 10.5758/vsi.2019.35.4.241.
- Pruitt LA. The effects of radiation on the structural and mechanical properties of medical polymers. *Adv Polym Sci* 2003;162:63-93. Doi: 10.1007/3-540-45668-6\_3.
- Debus ES, Diener H. Reconstructions following graft infection: An unsolved challenge. *Eur J Vasc Endovasc Surg* 2017;53:151-2. doi: 10.1016/j.ejvs.2016.11.006.
- Rais O, Lundström B, Angquist KA, Hallmans G. Bilateral aneurysm of dacron graft following aorto-femoral graft operation. A case report. *Acta Chir Scand* 1976;142:479-82.

8. Wilson SE, Krug R, Mueller G, Wilson L. Late disruption of Dacron aortic grafts. *Ann Vasc Surg* 1997;11:383-6. doi: 10.1007/s100169900065.
9. Pourdeyhimi B, Wagner D. On the correlation between the failure of vascular grafts and their structural and material properties: A critical analysis. *J Biomed Mater Res* 1986;20:375-409. doi: 10.1002/jbm.820200309.
10. Khaira HS, Vohra H. True aneurysm in a femoro-popliteal dacron graft -- a case report and literature review. *Cardiovasc Surg* 2002;10:644-6. doi: 10.1016/s0967-2109(02)00064-9.