

Median arcuate ligament syndrome: What is the best treatment?

İhsan Alur , Bilgin Emreca 

Department of Cardiovascular Surgery, Private Egekent Hospital, Denizli, Türkiye

Received: July 03, 2023 Accepted: August 16, 2023 Published online: October 25, 2023

ABSTRACT

Median arcuate ligament syndrome is a rare condition that is usually recognized late. Chronic postprandial abdominal pain, weight loss, loss of appetite, nausea, and diarrhea are usual symptoms due to the median arcuate ligament's mechanical compression on the celiac trunk and celiac plexus. The gold standard in treatment is to eliminate the mechanical compression of the median arcuate ligament on the celiac trunk and celiac plexus. In this article, we present a 49-year-old female patient who previously underwent endovascular intervention but whose complaints were not relieved and who underwent surgical treatment.

Keywords: Abdominal pain, celiac plexus, compression, median arcuate ligament release, surgery.

Median arcuate ligament syndrome (MALS) or celiac artery compression syndrome is a condition characterized by abdominal pain, weight loss, and loss of appetite as a result of mechanical compression of the median arcuate ligament on the celiac trunk and celiac plexus. It occurs in an estimated 2/100,000 patients.^[1] It is more common in women than men.^[1,2] It has also been reported in the pediatric patient group.^[1,2]

Clinical findings were chronic postprandial abdominal pain in 80% of cases, weight loss in 48%, murmur on auscultation in 35%, nausea in 9.7%, and diarrhea in 7.5%.^[2,3] Diagnosis is made by color Doppler ultrasound or computed tomography angiography. Inflammatory bowel diseases and anxiety disorder should be considered in the differential diagnosis. The gold standard in treatment is to eliminate the mechanical compression of the median arcuate ligament on the celiac trunk and celiac plexus. Therefore, surgical treatment seems to be the best option for patients diagnosed with MALS. In this article, a patient who underwent endovascular intervention but whose complaints were not relieved and who underwent surgical treatment was reported.

years and had increased since the last six months. In her gastroenterological examination, no pathology could be found to explain these symptoms. Later diagnosed with MALS on computed tomography angiography by interventional radiology. With the conventional mesenteric angiography technique, 80 to 90% stenosis was detected in the celiac artery, and the stenosis was resolved by placing a 6×27 mm stent (Figure 1a, b). The patient's abdominal pain complaints disappeared temporarily but started again after one week. In the control angiography performed by the interventional radiologist, the stent was found to be broken (Figure 2a, b), and surgical intervention was recommended to the patient. Open surgical intervention was scheduled after the completion of preoperative evaluations. A median laparotomy was performed above and below the umbilicus, following preparations under sterile conditions under general anesthesia. The celiac trunk, main hepatic artery, splenic artery, left gastric artery, and infrarenal aorta were released by encircling with a vessel tape. The stent was palpated proximal to the celiac trunk. There was no pulse distal to the stent. The ligament on the celiac

CASE REPORT

A 49-year-old female patient had complaints of abdominal pain, fear of eating (cibophobia), weight loss, abdominal distention, belching, constipation, loss of appetite, and nausea that had persisted for five

Corresponding author: İhsan Alur, MD. Özel Egekent Hastanesi Kalp ve Damar Cerrahisi Bölümü, 20125 Merkezefendi, Denizli, Türkiye.
E-mail: veyseltemizkan@yahoo.com

Citation:

Alur İ, Emreca B. Median arcuate ligament syndrome: What is the best treatment?.
Cardiovasc Surg Int 2023;10(3):177-179. doi: 10.5606/e-cvsi.2023.1552.

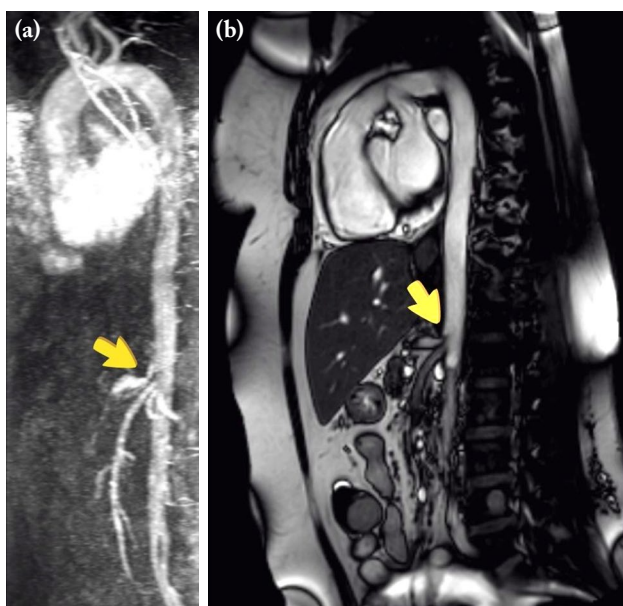


Figure 1. (a) Severe stenosis and poststenotic dilatation of the celiac artery in computed tomography angiography (yellow arrow); (b) severe stenosis and poststenotic dilatation of the celiac artery on magnetic resonance imaging (yellow arrow).

trunk and plexus was released with electrocautery. Intravenous 5,000 IU unfractionated heparin was administered. After an appropriate activated clotting time (ACT) was reached (ACT>150), bypass grafting was performed between the infrarenal aorta (Figure 3a) and the main hepatic artery (Figure 3b) using an

8 mm Dacron graft by tunneling from the intestinal mesos behind the stomach and in front of the duodenum/pancreas. The postoperative period was uneventful. The patient was discharged on the sixth postoperative day.

DISCUSSION

The existence of this disease is still controversial, and its diagnosis depends on the elimination of other possible causes of abdominal pain. The symptoms of MALS may not cause chronic mesenteric ischemia, and the pathophysiology of this disease is still not fully understood. However, a prospective cohort study using ischemia function testing demonstrated long-term benefit in approximately 80% of treated cases.^[4] Patients treated nonoperatively appear to have worse outcomes.^[2]

The main etiology of this disease is anatomical, as the median arcuate ligament mechanically compresses the celiac trunk and celiac plexus. In other words, since the main cause is anatomical, the treatment of the disease is to eliminate this pressure.^[2] The stent is broken or kinked due to mechanical compression. In this case, an endovascular intervention was performed one month ago, a stent was placed, but the patient's complaints started again, as stent fracture occurred one week later. Open surgery, minimally invasive procedures, or laparoscopic methods are applied.^[3,5]

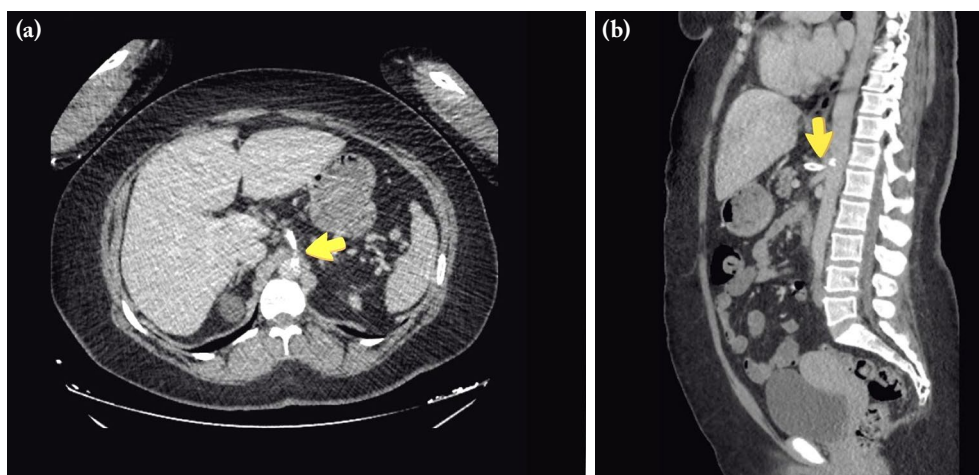


Figure 2. (a) One week after endovascular stent placement, computed tomography angiography (transverse section) shows that the stent is broken and thrombosed (yellow arrow); (b) computed tomography angiography (coronal section) shows that the stent is broken and thrombosed (yellow arrow).

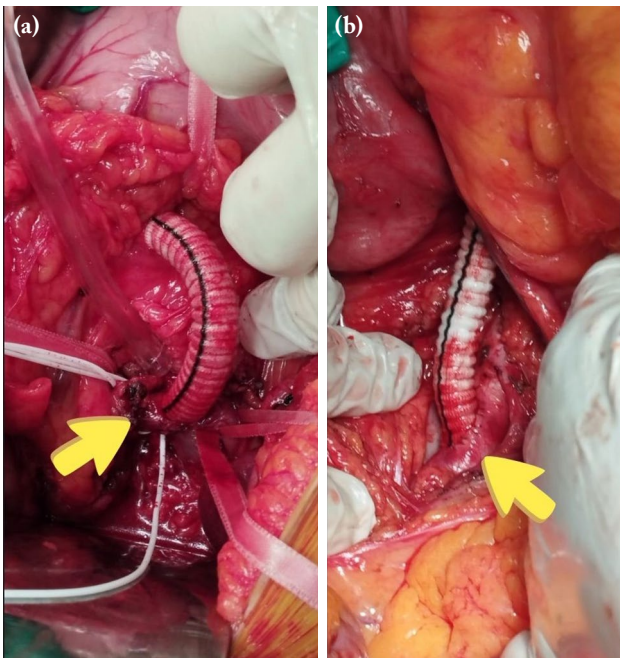


Figure 3. (a) Intraoperative view of the anastomosis between the infrarenal abdominal aorta and the Dacron graft (yellow arrow); (b) intraoperative view of the anastomosis between the hepatic artery and the Dacron graft (yellow arrow).

Whatever the method is, it should aim to eliminate compression.

Postprandial intestinal angina, cibophobia, weight loss, nausea, and vomiting are prominent complaints in MALS.^[2] In our case, epigastric pain/rumbling, cibophobia, abdominal bloating, belching, constipation, loss of appetite, and nausea were present in accordance with the literature.

Bypass grafting seems to be the most appropriate surgical treatment in some cases. Revascularization is performed by providing antegrade arterial inflow from the thoracic or supraceliac aorta or retrograde arterial inflow from the infrarenal aorta.^[2] For anatomical convenience, we performed bypass grafting between the infrarenal aorta and the main hepatic artery in our case.

In MALS, cutting the median arcuate ligament or releasing the fibrotic celiac ganglion by incision relieves pressure to a large extent and provides symptomatic relief.^[3,5] The most suitable lesion for an endovascular procedure is a short-segment (<10 cm) lesion close to the celiac artery or superior mesenteric artery ostium.^[2] In recent years, minimally invasive or laparoscopic methods have also been applied

in appropriately selected patients.^[3,5] Long-term follow-up data (over five years) after surgical management are lacking. In our case, stenting was previously performed, the stent was fractured and occluded within a week, symptoms relapsed, and the final treatment was open surgery. Ganglionectomy can also be performed if there is a neuropathic component. The celiac plexus was also released during the surgery. After the surgical treatment, the patient's complaints disappeared. It was observed that the patient's complaints completely resolved in the postoperative third month.

In conclusion, decompression of the median arcuate ligament's constriction of the celiac artery and plexus provides symptomatic relief in MALS. Bypass grafting seems to be the most appropriate treatment for the surgical treatment of some cases.

Patient Consent for Publication: A written informed consent was obtained from the patient.

Data Sharing Statement: The data that support the findings of this study are available from the corresponding author upon reasonable request.

Author Contributions: All authors contributed equally to the article.

Conflict of Interest: The authors declared no conflicts of interest with respect to the authorship and/or publication of this article.

Funding: The authors received no financial support for the research and/or authorship of this article.

REFERENCES

1. Iobst TP, Lamb KM, Spitzer SL, Patel RN, Alrefai SS. Median arcuate ligament syndrome. *Cureus* 2022;14:e22106. doi: 10.7759/cureus.22106.
2. Emreca B, Önem G, Baltalarlı A. İntestinal anjina: Karın ağrısının ender bir nedeni. *Turk Gogus Kalp Dama* 2008;16:269-73.
3. Sun Z, Zhang D, Xu G, Zhang N. Laparoscopic treatment of median arcuate ligament syndrome. *Intractable Rare Dis Res* 2019;8:108-12. doi: 10.5582/irdr.2019.01031.
4. Björck M, Koelemay M, Acosta S, Bastos Goncalves F, Kölbel T, Kolkman JJ, et al. Editor's choice - management of the diseases of mesenteric arteries and veins: Clinical practice guidelines of the European Society of Vascular Surgery (ESVS). *Eur J Vasc Endovasc Surg* 2017;53:460-510. doi: 10.1016/j.ejvs.2017.01.010.
5. Birkhold M, Khalifeh A, Nagarsheth K, Kavic SM. Median arcuate ligament syndrome is effectively relieved with minimally invasive surgery. *JSLs* 2022;26:e2022.00067. doi: 10.4293/JSLs.2022.00067.