

Coexistence of pulmonary stenosis and pulmonary artery aneurysm in a young patient: a case report

Anıl Özen, Aytaç Çalışkan, Utku Ünal, Bahadır AYTEKİN, Erman KIRIŞ, Boğaçan AKKAYA, Levent BİRİNCİOĞLU

Received: November 10, 2014 Accepted: February 08, 2014 Published online: April 17, 2015

ABSTRACT

A 22-year-old female patient diagnosed with stenosis and regurgitation of the dome-shaped pulmonary valve presented with dyspnea. She also had significant dilation of the pulmonary artery which extended to the left pulmonary hilum. The patient was treated surgically with infundibular myectomy, enlargement of the transannular right ventricular outflow with a pericardial patch, pulmonary valve replacement with a 25 mm stentless bioprosthetic valve and plication of the main pulmonary artery and the left pulmonary artery. We believe that using her own tissue for the reconstruction of the pulmonary artery aneurysm and pulmonary valve replacement through a stentless bioprosthesis with a minimum gradient and full competence to prevent the dilation of the pulmonary artery may be an ideal treatment option.

Keywords: Pulmonary artery aneurysm; pulmonary artery plication; pulmonary valve replacement; stentless bioprosthesis.

Pulmonary artery aneurysm (PAA) is a rare disease which may be idiopathic or secondary to other pathologies, either, such as pulmonary valve stenosis, congenital cardiac anomalies associated with pulmonary hypertension, Behçet's disease, trauma and infections.^[1,2] The natural history of the disease is not clearly understood and currently no definite guideline recommendations are available for the optimal treatment.

Post-stenotic dilatation frequently progresses to PAA. Herein, we discuss a female case of stenosis and regurgitation of the dome-shaped pulmonary valve with a significant aneurysm of the pulmonary artery.

CASE REPORT

We present a 22-year-old female patient diagnosed with PAA concomitant with pulmonary valvular stenosis. She suffered from dyspnea, palpitation, and fatigue. She had no past medical history of infection or trauma. Physical examination revealed a 2/6 systolic ejection murmur on the left sternal border. Posteroanterior chest X-ray revealed an enlarged pulmonary artery. Transthoracic echocardiography revealed pulmonary artery stenosis with a gradient of 85/55 mmHg. Pulmonary valve was thick and presented a dome-shape opening with a significant dilatation of the pulmonary artery which was 5.1 cm.

Computed tomography of the pulmonary artery showed that the pulmonary artery diameter at the valvular level was 22 mm. The pulmonary artery had a fusiform aneurysm starting from the supra-ventricular level with a maximum diameter of 49 mm (Figure 1). In addition, other differential diagnoses such as Behçet's disease and other vasculitides were excluded by the rheumatology team.

During surgery, median sternotomy was performed and pericardial patch was prepared and exposed to glutaraldehyde. The pulmonary aneurysm extended up to the left pulmonary hilum (Figure 2). A vertical incision from the right ventricular outflow tract (RVOT) through the pulmonary artery was made for the exposure of the pulmonary valve and the pulmonary trunk. The main pulmonary artery and the left pulmonary artery branches were placated circularly using 4/0 prolene sutures. The valve was excised and the pulmonary incision was extended to the ventricular infundibulum with septal myectomy. The RVOT was relieved and controlled with a 23-sized hegar buji. A 25 mm stentless

Department of Cardiovascular Surgery, Türkiye Yüksek İhtisas Hospital, Ankara, Turkey

Corresponding author: Anıl Özen, M.D. Türkiye Yüksek İhtisas Hastanesi Kalp ve Damar Cerrahisi Kliniği, 06230 Sıhhiye, Ankara, Turkey.
Tel: +90 533 - 736 43 43 e-mail: ozenanil@hotmail.com

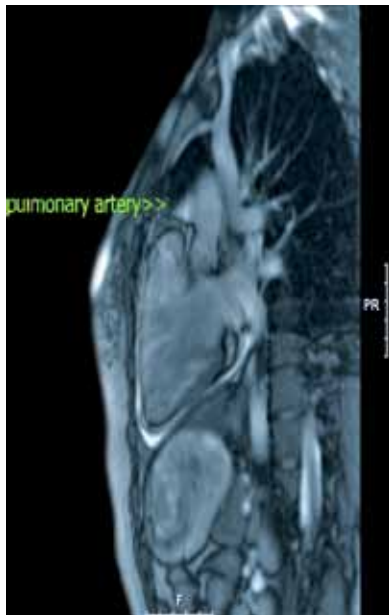

Figure 1. Fusiform aneurysm of the pulmonary artery.

SOLO bioprosthetic valve (SORIN Biomedica Cardio S.r.l.; Saluggia, Italy) was replaced to the pulmonary annulus (Figure 3). The annular gap was completed using a transannular pericardial patch. Intraoperative echocardiography revealed a gradient at the RVOT. Therefore, we enlarged the RVOT by myectomy and closed the infundibular incision using the pericardial patch facilitating a dilatation of the RVOT (Figure 4). No inotropic support was required to wean off cardiopulmonary bypass. After a day of intensive care unit stay, she was discharged on the sixth postoperative day.

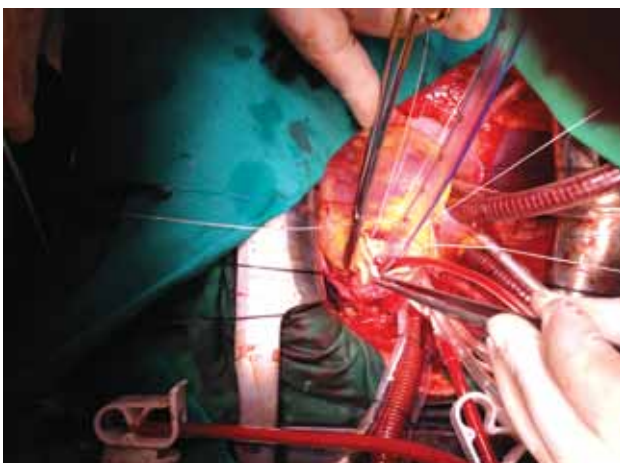


Figure 3. Implantation of the 25 mm stentless SOLO brand bioprosthetic valve to the pulmonary annulus.

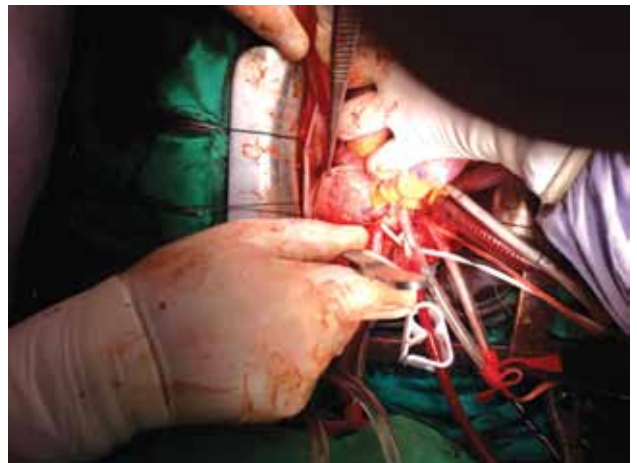


Figure 2. Intraoperative view of the pulmonary artery aneurysm.

DISCUSSION

Pulmonary artery aneurysm is a rare disease with common coexisting conditions. It can be secondary to other pathologies such as pulmonary valve stenosis, congenital cardiac anomalies associated with pulmonary hypertension, Behçet's disease, trauma and infections.^[1,2] Pulmonary stenosis may cause

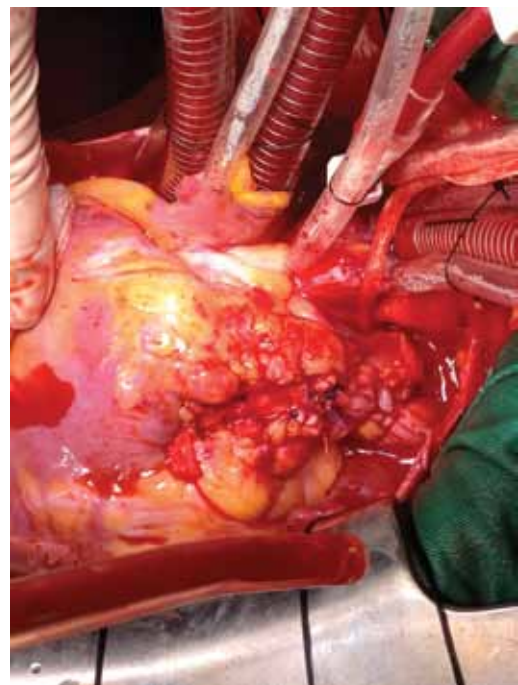


Figure 4. Closing the infundibular incision using the pericardial patch facilitating a dilatation of the right ventricular outflow tract.

excess volume or pressure load resulting in aneurysm formation.^[3]

Although conservative management of large aneurysms has been reported,^[4] documentation of rupture and dissection would make this strategy inadvisable for patients who would otherwise be considered suitable for surgery. Surgery should be considered in patients with dilatation of the pulmonary trunk and pulmonary arteries ≥ 5 cm, as in our case.

Valve reconstruction is the goal of all the surgical interventions, since restoration of anatomy and physiology employs the native tissue which allows for growth and potentially results in better long-term outcome. In case of repair failure or inconvenience, valve replacement would become inevitable.^[5] In our case, ideal body weight of the patient, pulmonary artery aneurysm as a coexisting anomaly and no requirement for growth were particularly critical issues for the choice of valve replacement.

In patients with significant pulmonary valve stenosis and or insufficiency, reconstruction of the RVOT is performed in cases with congenital heart disease, when there is discontinuity between the right ventricle and the pulmonary branch arteries. The patients with significant pulmonary valve annulus hypoplasia have been previously treated using transannular patch or valve conduit insertion. The transannular patch immediately relieves the right ventricular hypertension and enhances right ventricular growth proportionally with patient growth which is particularly important for the young patients. We enlarged the RVOT by myectomy and closed the infundibular incision using a pericardial patch facilitating the dilatation of the RVOT.

The mid-term results of porcine bioprosthetic valves in the RVOT reconstruction were reported as excellent in the literature.^[6] The main benefit of using bioprosthetic valve is avoidance of extensive dissection, easiness of implantation and good hemodynamic characteristics.^[6] Mechanical valves have been used for pulmonary valve replacement in a limited number of centers.^[7] Most centers recommend relatively large doses of warfarin and several reports of thromboses have been documented.^[8,9] In this case, we preferred a stentless bioprosthetic valve to obtain a larger effective orifice area and prevent complications of warfarin and re-intervention of RVOT.

Conclusion

For the patients who reach an ideal body weight and older than 18 years old with a pulmonary trunk aneurysm which extends to the left hilum, there is no ideal conduit which can provide a reliable anatomical size in the present condition. If the wall thickness of the aneurysm permits, plicating the aneurysm with semicircular continuous sutures and reconstruction of the RVOT by a stentless porcine valve to provide the widest choice of effective orifice may be the closest way for an ideal treatment option.

Declaration of conflicting interests

The authors declared no conflicts of interest with respect to the authorship and/or publication of this article.

Funding

The authors received no financial support for the research and/or authorship of this article.

REFERENCES

1. de Tomás Labat ME, Beltrán Beltrán S, Molina Naveros S, Navarro Botella F, Alvarez Soto D, Pérez Moro E, et al. Idiopathic pulmonary artery aneurysm: report of a case and review of the literature. *An Med Interna* 2005;22:329-31. [Abstract]
2. Imazio M, Cecchi E, Giammaria M, Pomari F, Tabasso MD, Ghisio A, et al. Main pulmonary artery aneurysm: a case report and review of the literature. *Ital Heart J* 2004;5:232-7.
3. Theodoropoulos P, Ziganshin BA, Tranquilli M, Elefteriades JA. Pulmonary artery aneurysms: four case reports and literature review. *Int J Angiol* 2013;22:143-8.
4. Casselman F, Meyns B, Herygers P, Verougstraete L, Van Elst F, Daenen W. Pulmonary artery aneurysm: is surgery always indicated? *Acta Cardiol* 1997;52:431-6.
5. Husain SA, Brown JW. When reconstruction fails or is not feasible: valve replacement options in the pediatric population. *Semin Thorac Cardiovasc Surg Pediatr Card Surg Annu* 2007;117-24.
6. Giamberti A, Chessa M, Reali M, Varrica A, Nuri H, Isgrò G, et al. Porcine bioprosthetic valve in the pulmonary position: mid-term results in the right ventricular outflow tract reconstruction. *Pediatr Cardiol* 2013;34:1190-3.
7. Haas F, Schreiber C, Hörer J, Kostolny M, Holper K, Lange R. Is there a role for mechanical valved conduits in the pulmonary position? *Ann Thorac Surg* 2005;79:1662-7.
8. Ilbawi MN, Lockhart CG, Idriss FS, DeLeon SY, Muster AJ, Duffy CE, et al. Experience with St. Jude Medical valve prosthesis in children. A word of caution regarding right-sided placement. *J Thorac Cardiovasc Surg* 1987;93:73-9.
9. Dos L, Muñoz-Guijosa C, Mendez AB, Ginel A, Montiel J, Padro JM, et al. Long term outcome of mechanical valve prosthesis in the pulmonary position. *Int J Cardiol*. 2011;150:173-6.