


## Dislodgement of the stent from its balloon due to entanglement in the previously implanted stent and retrieval of both stent with snaring: An interesting complication case

Mehmet Kış , Çisem Oktay , Özer Badak 

Department of Cardiology, Dokuz Eylül University Faculty of Medicine, İzmir, Türkiye

Received: September 18, 2024 Accepted: December 01, 2024 Published online: December 27, 2024

### ABSTRACT

Although stent dislodgement is a rare complication in interventional cardiology, its incidence has increased with the number of percutaneous coronary interventions. Stent dislodgement is a risk-laden complication concerning morbidity and mortality, and the management of embolized material can involve various techniques, including the snare technique, balloon retrieval with a small balloon, twirling/wire entrapment technique, and surgical methods. This case report highlighted a 65-year-old male patient who underwent coronary angiography for a diagnosis of non-ST elevation myocardial infarction. During the procedure, stent dislodgement occurred at the ostial left anterior descending artery/left main coronary artery distal region. The dislodged stents were successfully retrieved using the snare technique. The report emphasized techniques that can be utilized for the retrieval of embolized material in cases of stent dislodgement.

**Keywords:** Percutaneous coronary intervention, snare technique, stent dislodgement.

Stent dislodgement is a rare complication in interventional cardiology, but its frequency has increased with the growing number of percutaneous coronary interventions (PCIs). Material embolization during PCI can lead to significant morbidity and mortality risks. The incidence of stent embolization has been reported to be approximately 0.3 to 1.2%.<sup>[1]</sup>

With device and technical advances, percutaneous cardiovascular interventions have been increasingly used as an alternative to surgery for cardiac complications.<sup>[2,3]</sup> Various methods can be employed to retrieve the embolized material in the event of stent dislodgement during PCI. Dislodgement stents can be retrieved using techniques such as the snare technique, balloon retrieval with a small balloon, twirling/wire entrapment technique, and surgical methods.<sup>[2,3]</sup> While there is no gold standard method, a versatile approach should be attempted. In this case report, we emphasized the successful retrieval of dislodged stents using the snare technique in the ostial left anterior descending artery (LAD)/left main coronary artery (LMCA) distal region and discussed techniques for managing embolized material in cases of stent dislodgement.

### CASE REPORT

A 65-year-old male patient with comorbid hypertension and diabetes mellitus was admitted to the emergency department with chest pain. The electrocardiogram showed sinus rhythm and a high-sensitivity troponin I of 53.4 ng/L. Bedside echocardiography revealed a left ventricular ejection fraction of 50%. The patient was then taken to the coronary angiography (CAG) lab with a preliminary diagnosis of non-ST elevation myocardial infarction. A 6F sheath was placed in the right femoral artery, and JL4 and JR4 diagnostic catheters were used. Coronary angiography revealed normal LMCA, 40% lesion in the LAD ostial segment, 90% lesion in the D2 ostial segment, 90% lesion in the LAD beyond D3, 90%

**Corresponding author:** Mehmet Kış, MD. Dokuz Eylül Üniversitesi Tıp Fakültesi Kardiyoloji Anabilim Dalı, 35340 İnciraltı, İzmir, Türkiye.  
E-mail: drmehmet.kis@hotmail.com

### Citation:

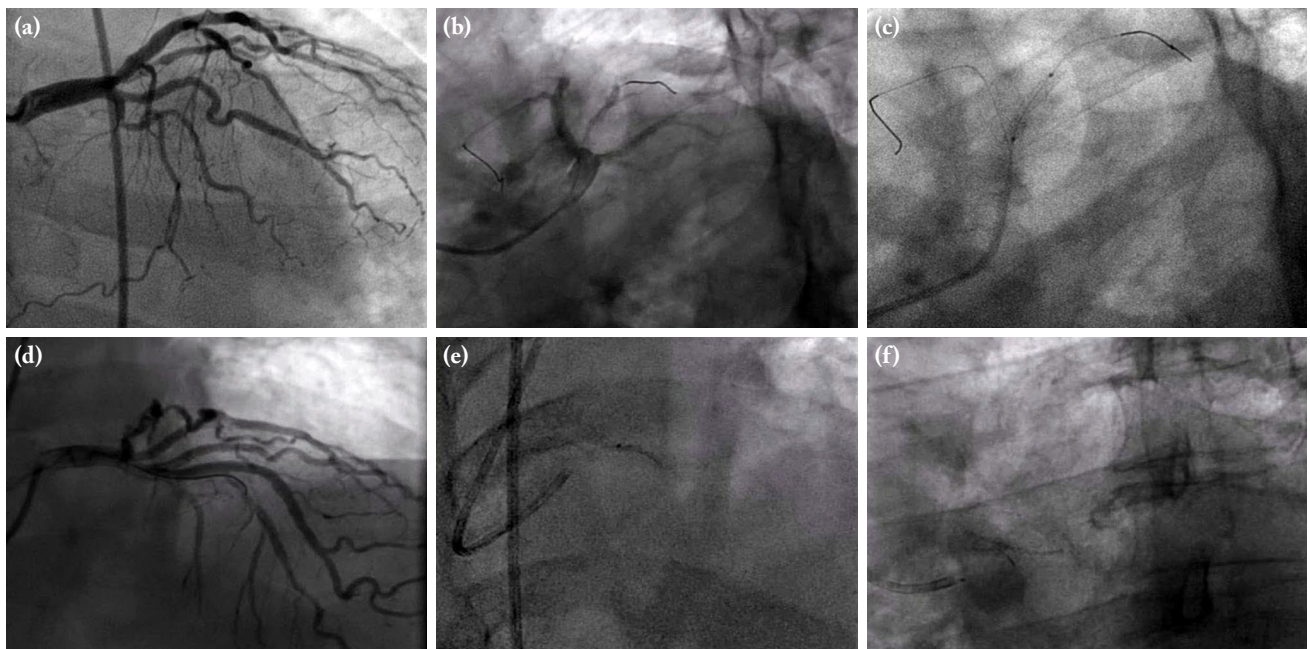
Kış M, Oktay Ç, Badak Ö. Dislodgement of the stent from its balloon due to entanglement in the previously implanted stent and retrieval of both stent with snaring: An interesting complication case. *Cardiovasc Surg Int* 2025;12(1):78-82. doi: 10.5606/e-cvsi.2025.1743.

thrombus-containing lesion in the internal mammary artery (IMA) ostial segment, 40% lesion in the circumflex artery mid segment, and a dominant right coronary artery with plaque (Figure 1a). As an initial strategy, it was planned to first stent the culprit IMA lesion, then evaluate the mid-LAD lesion, and place a stent if necessary. A written informed consent was obtained from the patient. Subsequently, a 6F EBU (extra backup) 3.5-cm guiding catheter was positioned in the LMCA. The IMA and LAD lesions were crossed using a floppy guidewire (Figure 1b). After IMA predilatation with a 2.0×15 mm percutaneous transluminal coronary angioplasty balloon, a 2.75×18 mm drug-eluting stent (DES) was not able to cross the IMA lesion, so a 2.5×18 mm DES was implanted (Figure 1c). At the stage when pushing force was applied to advance the stent into the IMA, the LAD wire accidentally dislodged from the LAD into the aortic root. Therefore, the LAD wire was reinserted after IMA stenting. Afterward, an attempt was made to advance the 2.75×18 mm DES to the middle LAD lesion. However, the stent could not pass through the proximal LAD segment. A 2.5×18 mm DES, which was tried later, encountered resistance

in the same region and could not be advanced to the middle LAD as well. As a result of careful evaluation to understand the reason, it was thought that there might be a possible interaction with the stent placed proximal to the IMA. Therefore, an attempt was made to slowly withdraw the stent, which was tried to be advanced to the middle LAD. However, during the process, the stent dislodged from the balloon and became stuck in that segment (Figures 1d, e).

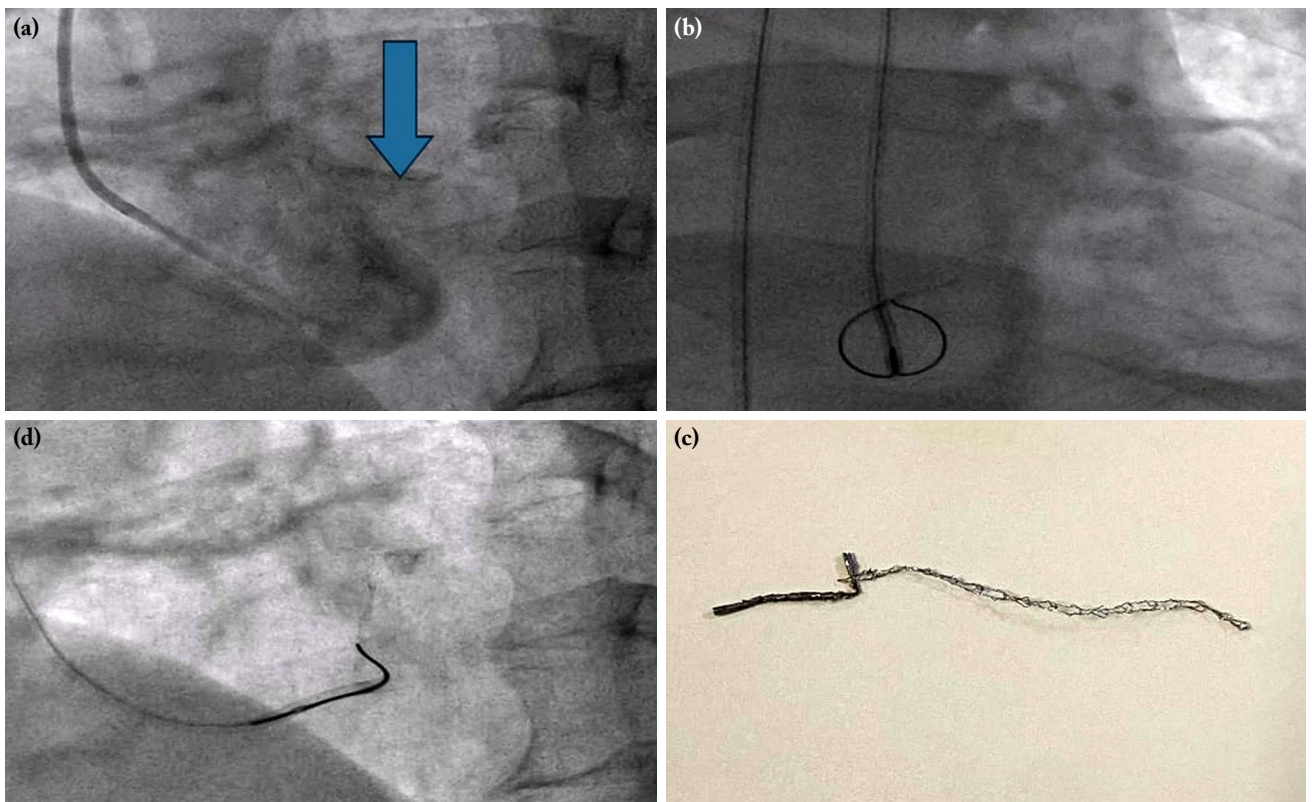
The lost stent was captured from the distal LMCA/ostial LAD using a 2-mm microsnare. During retrieval, the stent fell from the catheter tip into the ascending aorta/left sinus of valsalva. On follow-up imaging, the stent was observed to be immobile. Attempts to retrieve it with a snare were unsuccessful (Figure 1f). The patient was transferred to coronary intensive care with stable hemodynamics. Intravenous tirofiban infusion was started. The case was presented to the cardiology and cardiovascular surgery joint council.

Following the decision to attempt retrieval with a snare during the consultation, the patient was brought back to the CAG laboratory. A 6F EBU



**Figure 1.** (a) Presence of IMA ostial and LAD lesions in CAG. (b) Internal mammary artery and LAD lesions crossed using a floppy guidewire. (c) After predilatation with a 2.0×15 mm percutaneous transluminal coronary angioplasty balloon, a 2.5×18 mm DES was implanted in the IMA ostial lesion. (d) A 2.5×18 mm DES could not be advanced through the LAD lesion. (e) During retrieval, the stent was observed to have dislodged at the distal LMCA/proximal LAD. (f) The stent was attempted to be retrieved from the distal LMCA using a snare.

IMA: Internal mammary artery; LAD: Left anterior descending; CAG: Coronary angiography; DES: Drug-eluting stent; LMCA: Left main coronary artery.



**Figure 2.** (a) On follow-up imaging, the stent was observed to be immobile in the ascending aorta (the lost stent is indicated by the arrow). (b) The lost stent was captured with a snare. (c) The lost stent was pulled into the guiding catheter using the snare. (d) Postprocedure material.

3.5-cm guiding catheter was positioned in the LMCA. The stent, which had remained stable at the LMCA ostium and was directed towards the aortic root, was captured with a snare (Figures 2a, b). During the retrieval attempt, unexpected resistance was encountered. The stent was extracted using the snare through the guiding catheter (Figure 2c). It was observed that the stent had an extended portion at the tip of the snare, indicating that the stent included a part of the IMA stent. It was determined that the stent intended for the LAD had passed through the citrated segments of the IMA stent ostial region, which prevented its advancement and led to dislodgement. During the retrieval attempt, it was noted that the IMA stent had also extended and then retracted (Figure 2d). It was thought that the guidewire passed through the protruding part of the IMA stent struts during the rewiring stage for the LAD lesion after IMA stent placement, therefore LAD stent advancement was blocked by IMA stent struts. The procedure was then continued with LAD

PCI. The procedure was completed with TIMI 3 flow. The patient was discharged in good health after four days.

## DISCUSSION

Material embolization during coronary angioplasty procedures, although rare, significantly increases morbidity and mortality. The incidence of stent dislodgement has been estimated at approximately 1.2%.<sup>[1]</sup> When stent dislodgement occurs, the primary objective is to employ maneuvers that minimize harm to the patient and prevent the stent from embolizing, particularly to the cerebrovascular system.<sup>[1,3]</sup> Various techniques are available for retrieving embolized material, and the choice of technique may depend on the diversity of equipment in the catheterization laboratory, the patient's clinical condition, and the operator's clinical experience.

Factors increasing the risk of stent dislodgement include coronary tortuosity and calcification, attempting to advance the stent without adequate vessel preparation, direct stenting, using a small guiding catheter (e.g., 5F catheter), advancing a stent through a previously deployed stent, and continuing to forcefully retract the stent into the guiding catheter despite resistance.

In our case, during rewiring, the LAD wire passed through the struts of the IMA stent. Therefore, the LAD stent could not be advanced, and during the retraction of the LAD stent, the IMA stent was dislodged along with it.

In cases where other treatment methods fail, the technique of crushing the lost stent against the vessel wall can be performed using another stent. However, this technique increases the metal burden and should be applied with caution.<sup>[4]</sup> If the wire position on the stent is lost or the stent cannot be retrieved, this technique may serve as an alternative.<sup>[4,5]</sup>

The small balloon technique involves advancing a small balloon towards the stent when the wire position is preserved, inflating the balloon distal to the stent, and withdrawing the lost stent along with the balloon.<sup>[6,7]</sup> If the balloon has partially advanced through the stent, inflating it in the proximal midsection of the lost stent and withdrawing the system can be attempted.<sup>[4]</sup>

A variety of snares are used in both coronary and peripheral circulation. Snare loops are typically made of nitinol and are advanced into a microcatheter to be positioned around the lost material before being withdrawn into the catheter. The Amplatz Goose Neck snare (Medtronic, Inc., Minneapolis, MN, USA) features a single loop and is commonly used in daily practice.<sup>[4]</sup> If a snare is not available in the catheterization laboratory, an exchange wire of similar length (0.014 inches) and a smaller diagnostic catheter can be used to retrieve the lost material by removing and reintroducing the catheter from the distal end.<sup>[8,9]</sup>

When intervening in the LAD or circumflex coronary arteries, it is important to treat the distal coronary lesion first. Otherwise, stent protrusion will cause difficulties when stenting is required in the other vessel, and this may cause stent dislodgement. Stent dislodgement may also cause coronary flow restriction, and when the stent is removed, there may

be damage to the vascular endothelium. A previous study indicated that no reflow may occur when postdilatation is performed; therefore, it may be more logical to implant the stent to the stenosis area rather than the balloon.<sup>[10,11]</sup> It is important to note that each case of stent dislodgement is unique, and different techniques or combinations of techniques may need to be employed.

In conclusion, stent dislodgement is a rare complication in interventional cardiology, but its frequency has increased with the growing number of PCIs. The embolized material can be retrieved using techniques such as the snare technique, balloon retrieval with a small balloon, twirling/wire entrapment technique, and surgical methods. While there is no gold standard method, a versatile approach should be attempted. If stent dislodgement occurs while intervening in more than one coronary artery, and resistance is encountered when retracting the dislodged stent with the snare method, it should be considered that the dislodged stent may be attached to the ostial segment or to a proximally located stent implanted for another coronary artery.

**Data Sharing Statement:** The data that support the findings of this study are available from the corresponding author upon reasonable request.

**Author Contributions:** Idea/concept, analysis, data, literature review, writing: M.K., Ç.O.; Desing: Ö.B., M.K.; Control, critical review: Ö.B.; References, material: Ç.O., M.K., Ö.B.

**Conflict of Interest:** The authors declared no conflicts of interest with respect to the authorship and/or publication of this article.

**Funding:** The authors received no financial support for the research and/or authorship of this article.

---

## REFERENCES

- Alexiou K, Kappert U, Knaut M, Matschke K, Tugtekin SM. Entrapped coronary catheter remnants and stents: Must they be surgically removed? *Tex Heart Inst J* 2006;33:139-42.
- Güneş T, Alihanoglu Yİ, Alur İ, Yıldız BS. Easily removal of a malappositioned coronary stent with a guidewire. *Cardiovasc Surg Interv* 2015;2:47-48. doi: 10.5606/e-cvsi.2015.382.
- Iturbe JM, Abdel-Karim AR, Papayannis A, Mahmood A, Rangan BV, Banerjee S, et al. Frequency, treatment, and consequences of device loss and entrapment in contemporary percutaneous coronary interventions. *J Invasive Cardiol* 2012;24:215-21.

4. Brilakis ES, Garrett KN. Strategic approaches to coronary interventions. 3rd ed. Philadelphia: Lippincott Williams & Wilkins; 2005.
5. Abdel-Wahab M, Richardt G, Joachim Büttner H, Toelg R, Geist V, Meinertz T, et al. High-speed rotational atherectomy before paclitaxel-eluting stent implantation in complex calcified coronary lesions: The randomized ROTAXUS (Rotational Atherectomy Prior to Taxus Stent Treatment for Complex Native Coronary Artery Disease) trial. *JACC Cardiovasc Interv* 2013;6:10-9. doi: 10.1016/j.jcin.2012.07.017.
6. Brilakis ES, Best PJ, Elesber AA, Barsness GW, Lennon RJ, Holmes DR Jr, et al. Incidence, retrieval methods, and outcomes of stent loss during percutaneous coronary intervention: A large single-center experience. *Catheter Cardiovasc Interv* 2005;66:333-40. doi: 10.1002/ccd.20449.
7. Eggebrecht H, Haude M, von Birgelen C, Oldenburg O, Baumgart D, Herrmann J, et al. Nonsurgical retrieval of embolized coronary stents. *Catheter Cardiovasc Interv* 2000;51:432-40. doi: 10.1002/1522-726x(200012)51:4<432::aid-ccd12>3.0.co;2-1.
8. Foster-Smith KW, Garratt KN, Higano ST, Holmes DR Jr. Retrieval techniques for managing flexible intracoronary stent misplacement. *Cathet Cardiovasc Diagn* 1993;30:63-8. doi: 10.1002/ccd.1810300116.
9. Douard H, Besse P, Broustet JP. Successful retrieval of a lost coronary stent from the descending aorta using a loop basket intravascular retriever set. *Cathet Cardiovasc Diagn* 1998;44:224-6. doi: 10.1002/(sici)1097-0304(199806)44:2<224::aid-ccd21>3.0.co;2-1.
10. Can Y, Koçyiğit İ, Murat Aksoy MN. Incidence, treatment options and outcomes of stent loss during percutaneous coronary intervention: A single-center experience. *Sakarya Med J* 2020;10:565-71. doi: 10.31832/smj.747503.
11. Senoz O, Yurdam FS. The effect of postdilatation on coronary blood flow and inhospital mortality after stent implantation in st-segment elevation myocardial infarction patients. *IJCVA* 2021;7:132-139. doi: 10.4103/ijca.ijca\_35\_21.