

Surgical treatment of two different interventional cardiological complications at the same patient

Mustafa Seren,¹ Ömer Faruk Çiçek,² Ali Cemal Düzgün,¹ Salih Fehmi Katircioğlu¹

Received: April 08, 2014 Accepted: June 20, 2014

With the introduction of technological improvements, invasive cardiologic interventions have become increasingly used alternatives to surgery. Despite its numerous benefits, serious and potentially life-threatening complications of invasive cardiology interventions may occur. Herein, we report a case who developed two different complications due to an invasive cardiology intervention at different times. One of them was device embolization after transcatheter closure of atrial septal defect and the other was right ventricle perforation due to late pericardial tamponade-related percutaneous pericardiocentesis. Both complications associated with percutaneous intervention were surgically treated.

Keywords: Atrial septal defect; complication; occluder.

Atrial septal defect (ASD) is one of the most common congenital heart defects requiring procedural intervention. Transcatheter closure of ASD has gained wide popularity thanks to its high success rates, lack of scar, low morbidity, and shorter hospital stay. However, several complications have been reported, although rare, such as arrhythmia, embolization, erosion, fracture, malfunction, malposition, stroke, thrombus on device.^[1] The reported incidence of early device embolization after transcatheter ASD closure with Amplatzer septal occluder (AGA Medical Corp, Golden Valley, Minn) is approximately 0.5%.^[1] In this article, we report a case who developed two different complications due to an invasive cardiology intervention at different times: device embolization after transcatheter closure of ASD and right ventricle perforation due to late pericardial tamponade-related percutaneous pericardiocentesis. Both complications associated with percutaneous intervention were surgically treated.

CASE REPORT

A 41-year-old female patient was admitted to cardiology outpatient clinic with complaints of shortness of breath and tachycardia. Transthoracic echocardiography (TTE) and transesophageal echocardiography (TEE) demonstrated a 20 mm secundum ASD with adequate rims. The patient was scheduled for the deployment of percutaneous closure device, as ASD's morphology was suitable for percutaneous closure. A 26 mm

Amplatzer device was deployed successfully without any complications through catheterization. On the first day after implantation, repeated echocardiography and fluoroscopy detected device migration into the left ventricle (Figure 1). The patient was taken to operation room immediately. After institution of cardiopulmonary bypass, a longitudinal right atriotomy was performed. The edges of the ASD were retracted and the device was detected under anterior leaflet of the mitral valve. The device was gently detached from chordae and retrieved (Figure 2). Mitral valve leaflets and chordae were examined carefully for a possible traumatic injury, however, no pathology was noted. Atrial septal defect was repaired with the running suture technique. The postoperative course was uneventful. Warfarin was initiated due to atrial fibrillation. The patient was discharged on the fifth postoperative day. At two months postoperatively, the patient was admitted with shortness of breath and hypotension. International normalized ratio (INR) was high (>7) and TTE detected massive pericardial effusion. With fresh frozen plasma, INR was normalized. Echocardiography-guided percutaneous

¹Department of Cardiovascular Surgery, Ankara Training and Research Hospital, Ankara, Turkey

²Department of Cardiovascular Surgery, Türkiye Yüksek İhtisas Training and Research Hospital, Ankara, Turkey

Corresponding author: Mustafa Seren, M.D. Ankara Eğitim ve Araştırma Hastanesi Kalp ve Damar Cerrahisi Kliniği, 06340 Altındağ, Ankara, Turkey.
Tel: +90 312 - 595 30 00 e-mail: drmseren@hotmail.com

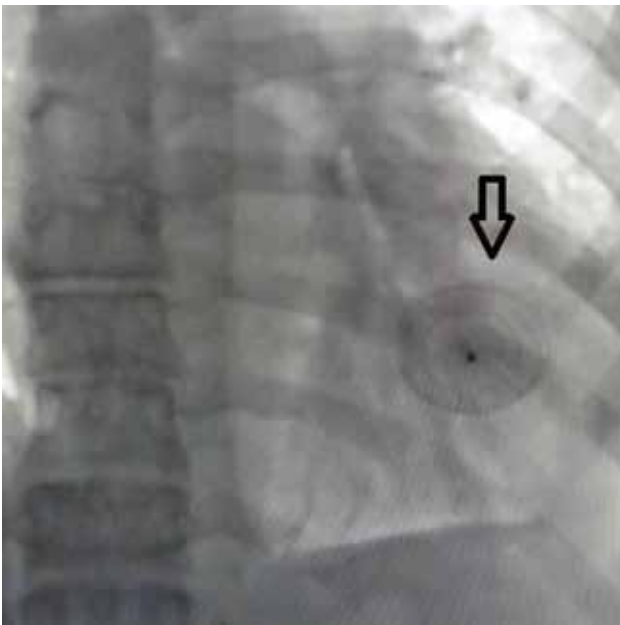


Figure 1. Fluoroscopy showing the Amplatzer occluder (arrow) in the left ventricle.

pericardiocentesis was performed with the subxiphoid approach. Catheter was seen in right ventricle during procedure. The patient was then taken to operation room immediately. Following median sternotomy, 1500 mL of bloody effusion was drained. Catheter from the right ventricle was removed and the puncture hole was sutured (Figure 3). The patient was discharged on the fourth postoperative day.

DISCUSSION

Percutaneous closure of ASD in adults has emerged as an alternative to surgery. Acute failure of these devices may occur due to several reasons, the most critical condition being poor patient and/or device selection.^[2] The other suggested mechanisms of acute failure are as follows: operator-related failure resulting from inadequate experience (learning curve), inaccurate placement, inadequate defect rim to hold the device, tearing of the interatrial septum, at the lower rim of the ASD during catheter, particularly, and device manipulation.^[3] According to Boysan et al.^[4] coughing may be an interesting reason for device embolization.

A part of the device or the whole device may embolize to the right or left atrium, to the main pulmonary artery, or even to the other parts of the

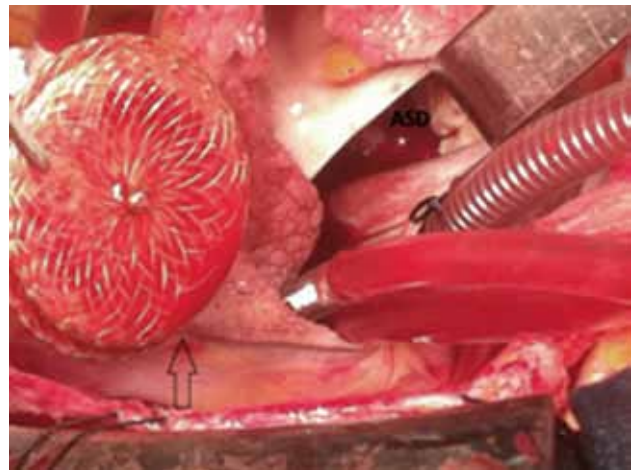


Figure 2. Intraoperative view of Amplatzer occluder (black arrow) and atrial transeptal approach to access the left ventricle. ASD: Atrial septal defect.

vascular tree. Embolization into left ventricle is rarer compared the right ventricle and pulmonary artery. Percutaneous retrieval of the embolized device is possible in about 70% of cases, and several techniques have been described, including the use of large sheaths, snares, or biopptomes.^[5] However, some authors suggest that embolization of device is always an indication for emergency surgical retrieval, which also permits a direct inspection of intra-cardiac structures that may have become injured.^[6] In our

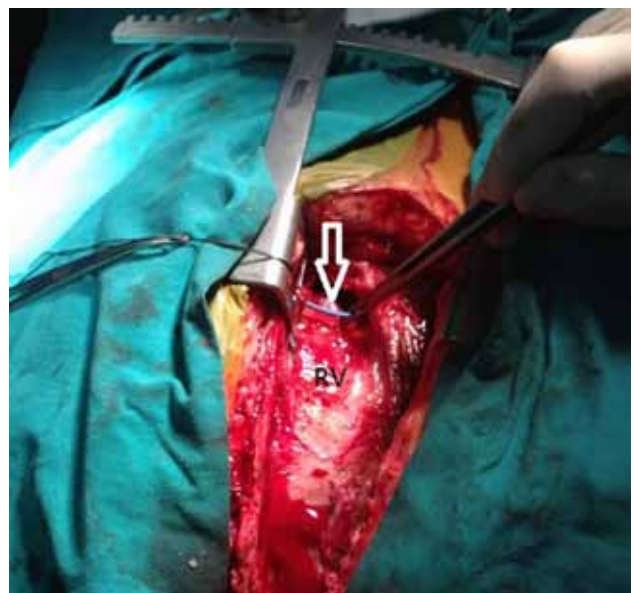


Figure 3. White arrow shows pericardiocentesis catheter in the right ventricle (RV).

patient, we also preferred surgical approach due to close relation of device with mitral valve in the left ventricle.

Late postoperative cardiac tamponade is an uncommon, but potentially lethal condition. Several authors have asserted that excessive anticoagulation in the postoperative period is responsible for late postoperative tamponade. Pericardiocentesis with catheter placement is highly effective and patients can be re-anticoagulated safely. In a Mayo Clinic series, echocardiography-guided pericardiocentesis was successful in withdrawing pericardial fluid or relieving tamponade in 97% of the procedures.^[7] Major complications including chamber laceration, intercostal vessel injury, pneumothorax requiring a chest tube, sustained ventricular tachycardia (VT), bacteremia, and death occurred in 1.2% of patients.^[8] Tsang et al.^[9] from Mayo Clinic reviewed 245 patients necessitating pericardiocentesis after cardiac surgery and showed 0.8% incidence of ventricular perforation. In our case, perforation of right ventricle was diagnosed during pericardiocentesis and the patient was then taken into operation urgently.

In conclusion, a careful echocardiographic assessment and procedure planning should be done for a percutaneous intervention. In addition, surgical back-up must be available in the hospital to cope with potentially lethal acute complications.

Declaration of conflicting interests

The authors declared no conflicts of interest with respect to the authorship and/or publication of this article.

Funding

The authors received no financial support for the research and/or authorship of this article.

REFERENCES

1. Amin Z, Hijazi ZM, Bass JL, Cheatham JP, Hellenbrand WE, Kleinman CS. Erosion of Amplatzer septal occluder device after closure of secundum atrial septal defects: review of registry of complications and recommendations to minimize future risk. *Catheter Cardiovasc Interv* 2004;63:496-502.
2. Sarris GE, Kirvassilis G, Zavaropoulos P, Belli E, Berggren H, Carrel T, et al. Surgery for complications of trans-catheter closure of atrial septal defects: a multi-institutional study from the European Congenital Heart Surgeons Association. *Eur J Cardiothorac Surg* 2010;37:1285-90.
3. Ulas MM, Lafci G, Tasoglu I, Kocabeyoglu S, Uzun A, Ozatik MA. The operative management of a displaced atrial septal occluder. *J Card Surg* 2010;25:382-4.
4. Boysan E, Cicek OF, Cicek MC, Hamurcu Z, Gurkahraman S. Surgical removal of an atrial septal occluder device embolized to the main pulmonary artery. *Tex Heart Inst J* 2014;41:91-3.
5. Levi DS, Moore JW. Embolization and retrieval of the Amplatzer septal occluder. *Catheter Cardiovasc Interv* 2004;61:543-7.
6. Kim JJ, Hijazi ZM. Clinical outcomes and costs of Amplatzer transcatheter closure as compared with surgical closure of ostium secundum atrial septal defects. *Med Sci Monit* 2002;8:CR787-91.
7. Tsang TS, Enriquez-Sarano M, Freeman WK, Barnes ME, Sinak LJ, Gersh BJ, et al. Consecutive 1127 therapeutic echocardiographically guided pericardiocenteses: clinical profile, practice patterns, and outcomes spanning 21 years. *Mayo Clin Proc* 2002;77:429-36.
8. Silvestry FE, Kerber RE, Brook MM, Carroll JD, Eberman KM, Goldstein SA, et al. Echocardiography-guided interventions. *J Am Soc Echocardiogr* 2009;22:213-31.
9. Tsang TS, Barnes ME, Hayes SN, Freeman WK, Dearani JA, Butler SL, et al. Clinical and echocardiographic characteristics of significant pericardial effusions following cardiothoracic surgery and outcomes of echo-guided pericardiocentesis for management: Mayo Clinic experience, 1979-1998. *Chest* 1999;116:322-31.