

Endovascular treatment of aortoiliac occlusion in a young patient with Behçet's disease

Murat Gedikoğlu

Received: September 19, 2015 Accepted: April 15, 2016 Published online: July 21, 2016

ABSTRACT

Behçet's disease is an autoimmune systemic disorder based on vasculitis which may affect the blood vessels of all sizes and sites, both arteries and veins. Although arterial involvement is rare, it is the major cause of death. Aneurysms are common in patients with Behçet's disease with a low incidence of artery stenosis or occlusion. An isolated common iliac artery or bilateral aortoiliac bifurcation stenosis were treated with balloon angioplasty and stent implantation in patients with Behçet's disease. Herein, we report a 40-year-old female case of Behçet's disease with aortoiliac occlusion treated with endovascular stent implantation.

Keywords: Aortoiliac occlusion; Behçet's disease; endovascular treatment; iliac artery stenosis; stent implantation.

Behçet's disease (BD) is a multi-system inflammatory disorder with characteristic pathological findings including recurrent oral and genital ulcers, skin lesions, and uveitis. Vasculitis is the predominant histopathological lesion in BD.^[1] Arteries and veins of all sizes and sites may be involved. Vascular involvement is typically seen in the form of superficial thrombophlebitis or deep vein thrombosis. Arterial manifestation is less frequent, but is a serious cause of morbidity and mortality. Aneurysm is more frequent than stenosis or occlusion with arterial involvement in BD.^[1,2] An isolated common iliac artery or bilateral aortoiliac bifurcation stenosis in patients with BD treated with balloon angioplasty and stent implantation have been reported in an only limited number of cases.^[3,4] Herein, we report a female case of BD with aortoiliac occlusion treated with endovascular stent implantation.

CASE REPORT

A 40-year-old woman with a five-year history of BD was admitted to our hospital with severe pain after only a few meters walking distance on both legs. Computed tomography (CT) angiography showed an occlusion at the distal aortic lumen, aortic bifurcation, and bilateral common iliac artery (Figure 1a).

Medical history revealed recurrent oral and genital ulcers, skin lesions, and uveitis since the age of 35 years. The pathergy test result was positive at the time

of diagnosis. She was on systemic immunosuppressive therapy including steroids, colchicine, and cyclophosphamide. She had also a history of deep vein thrombosis five years ago and nephrectomy for atrophic right kidney. She was a life-long non-smoker.

On physical examination, there were oral ulcers and skin lesions. Pulses were weakly palpable in the groin on both sides, but absent in the infrapopliteal arteries. The ankle-brachial index (ABI) was markedly reduced bilaterally to 0.58 on the right side and to 0.57 on the left side. Color Doppler ultrasonography (DUS) demonstrated a damped monophasic waveform on both common femoral arteries. Laboratory test results were as follows: hemoglobin 12.90 g/dL, erythrocyte sedimentation rate (ESR) 22 mm/h (normal range: 0 to 20 mm/h), and C-reactive protein (CRP) 7.23 mg/L (normal range: 0 to 6 mg/L). Serum complement was normal. There were no anti-nuclear antibodies and rheumatoid factor was negative. Other laboratory parameters were within normal ranges.

As the patient suffered from severe claudication, digital subtraction angiography was scheduled. Before angiography and subsequent treatment, potential risks and benefits were explained in detail, and a written

Department of Radiology, Medical Faculty of Başkent University, Adana, Turkey

Corresponding author: Murat Gedikoğlu, MD. Başkent Üniversitesi, Adana Dr. Turgut Noyan Uygulama ve Araştırma Merkezi Radyoloji Kliniği, 01250 Yüreğir, Adana, Turkey.

Tel: +90 532 - 651 84 60 e-mail: drmuratgedikoglu@gmail.com

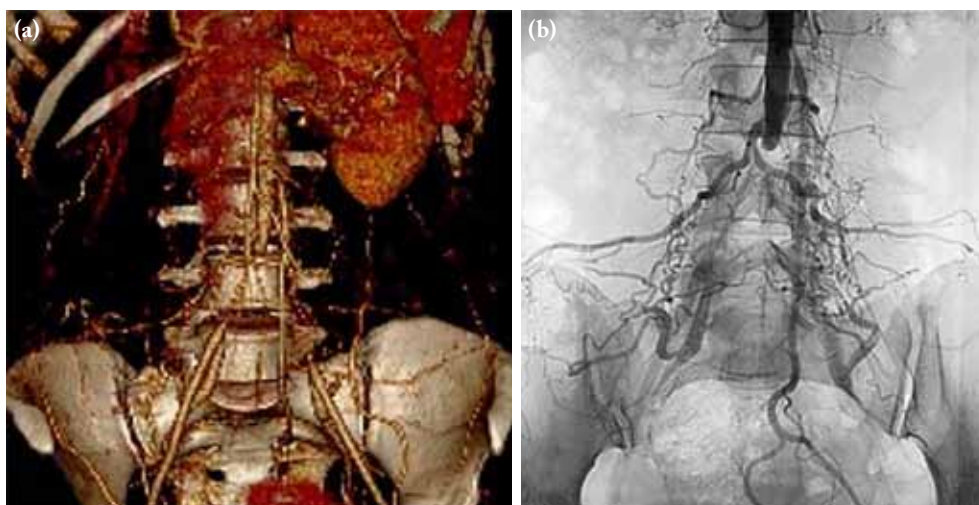


Figure 1. Computed tomography angiography (a) and pre-interventional angiography (b) showing chronic aortoiliac occlusion with reperfusion of the external iliac arteries via collaterals.

informed consent was obtained from the patient. The patient was punctured on the right brachial artery and a long sheath was placed in the abdominal aorta. Abdominal aortogram and pelvic arteriography revealed occlusion at the distal aortic lumen, aortic bifurcation, and bilateral common iliac artery (Figure 1b). Distal vessels were normal. After puncture of the common femoral artery on both sides, vascular sheaths (6F) were placed. Aortoiliac occlusion was

crossed subintimally from the aortic side using a stiff hydrophilic-coated 0.035 inch guidewire supported by a diagnostic catheter. Guide wires were grasped with a snare from the ipsilateral side and they were exchanged to super stiff wires. After cautious pre-dilatation of the occluded aortoiliac arteries with a 5 mm balloon, retrograde stents were placed using two 8x60 mm in size self-expanding nitinol stents with the “kissing stents” technique (Figure 2a). Complementary kissing

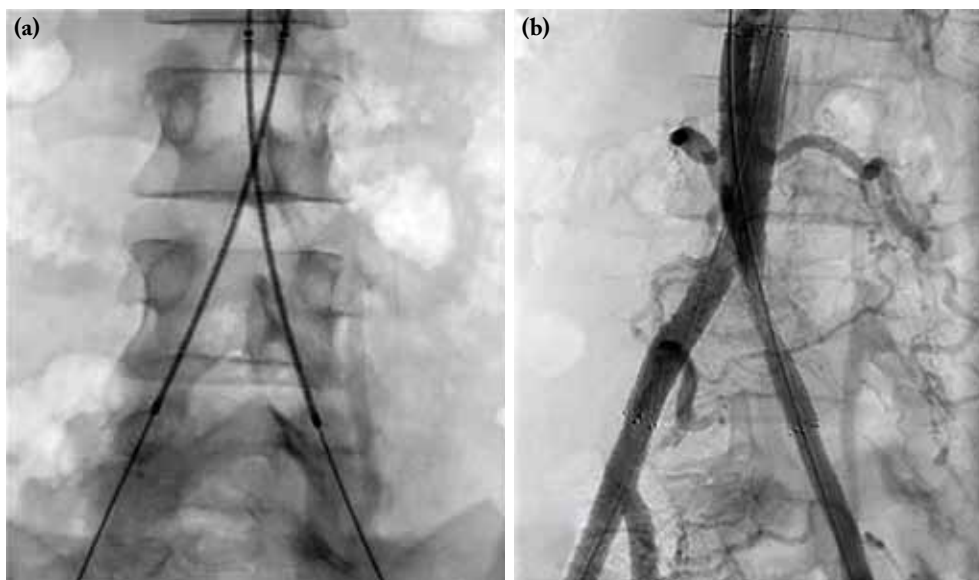


Figure 2. (a) Stent reconstruction with standard nitinol stents in “kissing” technique. (b) The final angiogram showing residual stenosis on the left side related to pressure-resistant plaque and an optimal result without residual stenosis on the right side.

balloon angioplasty was performed simultaneously with two 7x60 mm balloons to expand the stents to their nominal diameters. The final angiogram demonstrated residual stenosis (30 to 40% by visual estimation) on the left side related to pressure-resistant plaque. There was an optimal result without residual stenosis on the right side (Figure 2b). No procedure-related complications were observed. Brachial and femoral puncture sites were managed by manual compression. There was no early or late puncture site problem. The patient was discharged on the second hospital day. She was prescribed acetylsalicylic acid (100 mg/day).

The patient was scheduled for a follow-up visit at six months. She was able to walk regular distances without pain. She only complained of mild pain on the left side, when climbing stairs. Doppler waveform was triphasic on both common femoral arteries. Her ABI was normal (1,2) on the right side and acceptable (0.9) on the left side. Due to less invasive technique compared to DSA, CT angiography was obtained to check potential complications or recurrence. It showed no significant interval change in the residual stenosis on the left side (Figure 3a-c). No aortoiliac or femoral aneurysm appeared.

DISCUSSION

Behçet's disease is most common among the Mediterranean, Middle and Far East Asia populations along the old silk route. The etiology is still unclear, but likely to be multi-factorial. Although the usual

onset of disease is in the third decade of life, it can occur at any age.^[1] Men and younger patients often have more severe disease than women and older patients. Behçet's disease has various clinical features and progresses with unpredictable attacks and remissions. Vasculitis is considered to underlie these clinical manifestations.^[1,2] Vascular involvement may be seen in up to 50% of patients depending on the population studied. Involvement in BD can be arterial or, more commonly, venous and may involve both systems in a single patient. The most frequent type of vascular manifestation is superficial and deep vein thrombosis, mostly in the lower extremities. After the first vascular lesion, usually venous thrombosis, the risks are increased for other vascular lesions. Although rare, arterial involvement is the main predictor of morbidity and mortality. Arterial lesions are often isolated, but may be multiple and frequently coexist with venous thromboses. Arterial manifestation includes true aneurysm or pseudoaneurysm formation and less commonly stenosis or occlusion. The main locations of the arterial lesions are the aorta followed by the pulmonary and femoral arteries. Other reported arterial lesions include subclavian, common carotid, coronary, brachial, radial, ulnar, common iliac, external iliac, tibial, renal, cerebral, axillary, and splenic arteries.^[1,2,5-7] Our case had a history of deep vein thrombosis five years ago and claudication thereafter.

The diagnosis of disease is primarily based on clinical criteria, as there are no specific laboratory or histopathological findings. The ESR and CRP

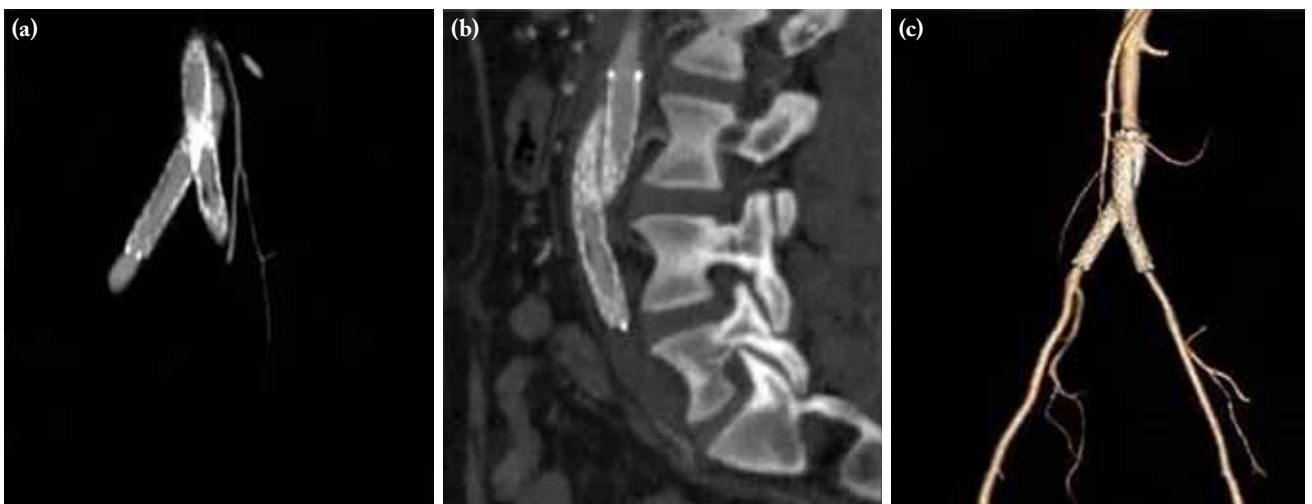


Figure 3. Computed tomography angiography (a-c) six months after intervention showing no significant interval change in the residual stenosis on the left side. No aortoiliac or femoral aneurysm appeared.

are usually moderately elevated; however, they do not correlate well with the disease activity. Previous studies recommended immunosuppressive therapy to normalize the ESR and CRP values preoperatively or before endovascular treatment.^[6,7] Postoperative therapy was also reported to be critically important to prevent recurrent aneurysmal disease or formation of pseudoaneurysms at the site of artery access.^[8,9]

Furthermore, vasculo-BD patients usually have a dramatic course and prognosis. Ischemia of the arterial wall due to an inflammatory obliteration of the vasa vasorum may result in true or false aneurysm formation with an increased incidence of rupture and bleeding. The rupture of a aneurysm is a major cause of death.^[5,6] Arterial complications may lead to difficult surgical problems, as surgical repair may provoke development of new aneurysms at the site of vascular interference or anastomosis and may be complicated by the graft thrombosis in high percentage of patients. To avoid surgical complications, endovascular treatment have been recommended increasingly, since it is less invasive and has fewer complications.^[5,8-10]

Although arterial stenosis or occlusion in BD is rare, nearly every major artery has been reported to be involved by this disease.^[6,11-13] Some of them were treated by balloon angioplasty and stent implantation to improve symptoms. In a previous study, long-term results in the recanalization of chronic iliac occlusions were acceptable compared to conventional surgical techniques.^[14] However, experience with endovascular treatment of the iliac artery stenosis or occlusion in BD and their long-term results are very limited. Only two cases of endovascular treatment of an isolated common iliac artery stenosis or bilateral aortoiliac bifurcation stenosis in patients with BD have been reported previously.^[3,4] To the best of our knowledge, our case, who presented with aortoiliac occlusion in BD, is the first case of this type reported. Because of severe claudication symptoms, angioplasty and stent implantation was performed for management of aortoiliac occlusion. At the time of the procedure, she was on systemic immunosuppressives and her ESR and CRP values were close to the upper of normal ranges. Endovascular treatment was successful, in our case, without any complication related to angiography and angioplasty.

Arterial punctures or insertion of a vascular sheath for angiography may induce either a thrombosis or a pseudoaneurysm formation in the puncture site.^[15] As

a result, CT angiography was obtained after six months for discovery of a new pseudoaneurysm, stenosis or occlusion. No aortoiliac or femoral aneurysm appeared. There was no significant interval change in the residual stenosis on the left side.

In conclusion, arterial stenosis or occlusion are extremely rare, particularly at the aortoiliac bifurcation or common iliac arteries due to Behçet's disease. Endovascular stent implantation with the "kissing stents" technique is an appropriate therapeutic choice for these patients. Not only the vascular or endovascular interventions, but also medical treatment strategy for the Behçet's disease should be taken into consideration.

Declaration of conflicting interests

The author declared no conflicts of interest with respect to the authorship and/or publication of this article.

Funding

The author received no financial support for the research and/or authorship of this article.

REFERENCES

1. Kontogiannis V, Powell RJ. Behçet's disease. *Postgrad Med J* 2000;76:629-37.
2. Sarica-Kucukoglu R, Akdag-Kose A, Kayabali M, Yazganoglu KD, Disci R, Erzen D, et al. Vascular involvement in Behçet's disease: a retrospective analysis of 2319 cases. *Int J Dermatol* 2006;45:919-21.
3. Ulsan Z, Karadag AS, Harman A, Boyvat F, Bilgic S. Right common iliac artery stenosis and stent insertion in Behçet's disease. *Cardiovasc J Afr* 2011;22:e4-6.
4. Jang S, Jeong MH, Jung HK, Lee KJ, Kim KH, Hong YJ, et al. Successful Stent Implantation for Aortoiliac Bifurcation Stenosis in a Young Patient with Behçet's Disease. *Korean Circ J* 2014;44:351-4.
5. Calamia KT, Schirmer M, Melikoglu M. Major vessel involvement in Behçet's disease: an update. *Curr Opin Rheumatol* 2011;23:24-31.
6. Park JH, Han MC, Bettmann MA. Arterial manifestations of Behçet disease. *AJR Am J Roentgenol* 1984;143:821-5.
7. Fei Y, Li X, Lin S, Song X, Wu Q, Zhu Y, et al. Major vascular involvement in Behçet's disease: a retrospective study of 796 patients. *Clin Rheumatol* 2013;32:845-52.
8. Liu CW, Ye W, Liu B, Zeng R, Wu W, Dake MD. Endovascular treatment of aortic pseudoaneurysm in Behçet disease. *J Vasc Surg* 2009;50:1025-30.
9. Kwon Koo B, Shim WH, Yoon YS, Kwon Lee B, Choi D, Jang Y, et al. Endovascular therapy combined with immunosuppressive treatment for pseudoaneurysms in patients with Behçet's disease. *J Endovasc Ther* 2003;10:75-80.

10. Ozeren M, Mavioglu I, Dogan OV, Yucel E. Reoperation results of arterial involvement in Behçet's disease. *Eur J Vasc Endovasc Surg* 2000;20:512-9.
11. Sagduyu A, Sirin H, Oksel F, Turk T, Ozenc D. An unusual case of Behçet's disease presenting with bilateral internal carotid artery occlusion. *J Neurol Neurosurg Psychiatry* 2002;73:343.
12. Toprak O, Ersoy R, Uzum A, Memis A, Cirit M, Akpolat T. An unusual vascular involvement in a patient with Behçet's disease: renal artery stenosis. *Am J Med Sci* 2007;334:396-8.
13. Nakamura H, Ueki Y, Horikami K, Miyake S, Hirao K, Tominaga M, et al. Vasculo-Behçet's syndrome with widespread arterial involvement. *Mod Rheumatol* 2001;11:332-5.
14. Uher P, Nyman U, Lindh M, Lindblad B, Ivancev K. Long-term results of stenting for chronic iliac artery occlusion. *J Endovasc Ther* 2002;9:67-75.
15. Kingston M, Ratcliffe JR, Alltree M, Merendino KA. Aneurysm after arterial puncture in Behçet's disease. *Br Med J* 1979;1:1766-7.